

eISSN : 2579-8324

pISSN : 2579-8323

**Alamat Korespondensi:**

Ruang Redaksi Andalas Obstetrics and Gynecology Journal, Lantai 3 PPDS Obstetri dan Ginekologi Universitas Andalas, RSUP DR. M. Djamil Padang, Jl. Perintis Kemerdekaan Padang, Sumatera Barat 25127

**Website:**

<http://jurnalobgin.fk.unand.ac.id/index.php/JOE>

**LITERATURE REVIEW****Colposcopy Findings In High-Grade Cervical Precancer Lesion**

Andi Friadi

*Affiliations:* Sub Division of Gynecological Oncology, Obstetrics and Gynecology Department, Faculty of Medicine, Andalas University, Dr. M. Djamil Central General Hospital Padang

*Correspondence:* Andi Friadi, email: [andifriadi19@gmail.com](mailto:andifriadi19@gmail.com), Hp: 085263076356

**Abstract**

*Cervical precancer lesion can generally be seen in the transformation zone. Colposcopy allows us to see an image of enlarge precancer lesion in the transformation zone. The colpocopist should consider some important things to determine the appearance of low-grade lesion or high-grade lesion. Two important things are the description of abnormal epithelium and the description of abnormal blood vessels. The description of the abnormal epithelial seen after administration of acetic acid 3-5%, acetowhite looks faster and disappears slower. The "white" lesion is more concentrated like the color of shells, with clear border and surface contour. To find the abnormal blood vessels more clearly, we can use the green filter. High-grade lesion shows rough mosaic and rough punctation or both. In addition, finding the cervical blood vessels can help us to determine high-grade lesion. By understanding the description of the epithelial cervix and abnormal blood vessels, we will easily distinguish high-grade lesions from low grade lesion.*

**Keywords:** cervical precancer, colposcopy findings

**INTRODUCTION**

Colposcopy accompanied by directional biopsy is the gold standard to establish a diagnosis of cervical precancer lesions. Colposcopy is a microscope that can help us to visualize the cervix with a magnification of 6 to 40 times. To be able to correctly interpret the description of the colposcopy, we need a knowledge of histopathological change occurs in the epithelial and cervical stroma. Epithelial is a layer that is not colored, while stroma has a red color due to blood vessels contained in there. The red color is reflected back to the examiner. Thickness, structure and density of epithelium can affect reflected light. In the epithelial of the precancer lesions, there is an increase in thickness and changes in the structure that is reflected to the examiner instead of the red color of the cervical stroma, but we will see white color (especially after the administration of acetic acid).<sup>1</sup> The white color with the strict boundary seen in the transformation zone is a pathognomonic finding in colposcopy to diagnose precancer lesion.<sup>2</sup>

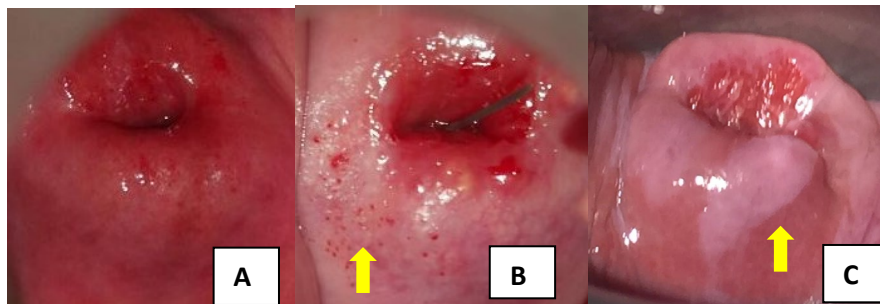
When acetic acid applied in the area of precancer lesion, the nucleoproteins that are precipitate in the precancer cells will obstruct the light, so that the light will be reflected and exhibit an *acetowhite* image. In low grade lesions, acetic acid will enter until the middle of the cervical epithelial, so that the white color will be slowly visible. While in high-grade lesion,

acetic acid administration will immediately show a clearer white color.<sup>1</sup> The clearer white lesion, then the longer white color is seen, this gives a picture of a high-grade of lesions.<sup>3</sup>

There are several agreements on the criteria that distinguish the extent of the high grade compare to low grade, such as *acetowhite* appearance after applied of acetic acid, firmly the border between the *acetowhite* area with the surrounding area, the blood vessel, and the description of atypical blood vessels.<sup>4</sup> To diagnose precancer lesion, the three main modalities which is cytology, colposcopy and histopathology should be interconnected. The abnormal cytology (pap smear) results will help the clinician to see and look for precancer lesions in the cervix.<sup>1</sup> Around 70% to 75% patients with the pap smear result of high-grade *Intraepithelial lesion* (HSIL) is a high-grade of precancer lesion (*cervical intraepithelial neoplasia* (CIN) 2-3), and about 1% to 4% is a cervical cancer.<sup>5</sup>

#### DESCRIPTION COLPOSCOPY FINDING OF PRECANCER LESION

Acetowhite appearance (figure 1) are paramount in assessing the description of the colposcopy, as this relates to the change of normal cervical epithelial (metaplasia) to the precancer lesion. In addition, three images of colposcopy that need to be considered are margin, surface contours and patterns of atypical blood vessels.<sup>1,2</sup>

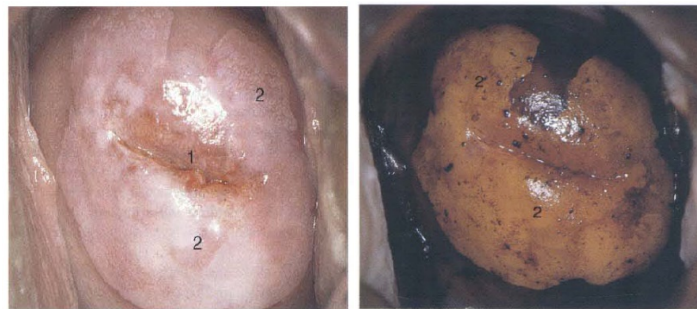


**Figure 1.** Acetowhite appearance. A. Normal, B. Metaplasia (yellow arrow) C. Precancer lesion (yellow arrow).

#### Acetowhite appearance

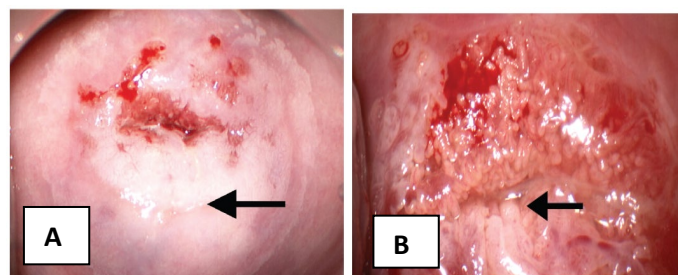
The depiction of a high-grade lesion after applied the acetic acid shows a thick *acetowhite* area, with clear/opaque white and a firmly border/edge.<sup>2</sup> For comparison, the normal cervical epithelial after applied the acetic acid does not exhibit white discoloration. This process occurs because in the normal cervical epithelial there is a high amount of glycogen and minimal amount of protein, whereas in the epithelial of a high-grade precancer lesion there are high amounts of protein (on cell membranes, nuclei and cytoplasm) but very little amount of glycogen. While in low-grade lesion have a lot of protein and glycogen, so when we applied the acetic acid shows the white color (*acetowhite*) is unclear and the iodine administration shows a faint yellow color (*weak and unequal staining*).<sup>1</sup>

*Acetowhite* changes is dynamic changes with its peak seen after 60-90 seconds of acetic acid administration. High-grade lesion will retain the color acetowhite longer (2-4 minutes) but low-grade lesion will fade rapidly.<sup>5</sup> Other modality to find precancer lesion is to perform Iodine test/ Schiller test. Iodine test, first introduced by Schiller in 1929, was used to exhibit a precancer lesion. A large squamous epithelium containing glycogen will be seen as brown color after iodine administration. Whereas in precancerous lesions containing keratin but less glycogen will give a yellow color post-administration of iodine.<sup>1,2</sup>



**Figure 2.** Iodine test. (source : Singer A, Monaghan JM, Quek SW, Deery ARS. *Diagnosis of Cervical Precancer - The use of colposcopy. Lower Genital Tract Precancer - Colposcopy, Pathology and Treatment. 2nd ed: Wiley-Blackwell; 2000. p. 97-160*)

The high-grade lesion is divided into two, based on the histopathology overview, the precancer lesion that exhibit dysplasia cells occupying until two-thirds of the cervical epithelial categorized as CIN 2. Meanwhile lesion that exhibit cell dysplasia occupy more than two-thirds are categorized as CIN 3.<sup>6</sup> Bowring et al added the size of *acetowhite* area is a variable that needs to be assessed.<sup>7</sup>



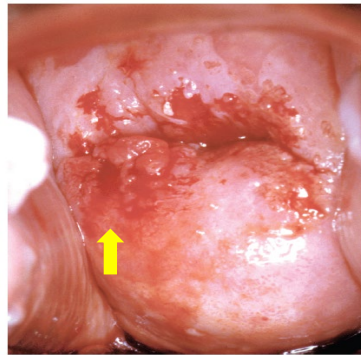
**Fig 3.** A. Inner border sign. (Black arrow) B. Rigde sign (Black arrow). (source: Bornstein J, Bentley J, Bösze P, Girardi F, Haefner H, Menton M, et al. 2011 Colposcopic Terminology of the International Federation for Cervical Pathology and Colposcopy. *Obstet Gynecol.* 2012;120:166-72)

The new colposcopy terminology was compiled by the *Committee of the International Federation of Cervical Pathology and colposcopying* adding two markers (figure 3) for high-

grade lesion namely "*inner border sign*" and "*Ridge sign*." The *Inner border sign* is a strict border between the thin acetowhite region and the thick acetowhite area of the same lesion.<sup>8</sup>

### Margin/border and contour surfaces of precancer lesion

In high-grade lesion, the outline of the margin/border shows a firm, regular and thicker than the surrounding epithelial.<sup>1</sup> Different from irregular and unequivocal low-grade lesion.<sup>5,6</sup> High-grade lesion can be seen inside a wider low-grade lesion, in the figure below, we find edges of the lesion show the internal border or demarcation more firmly.<sup>5</sup>



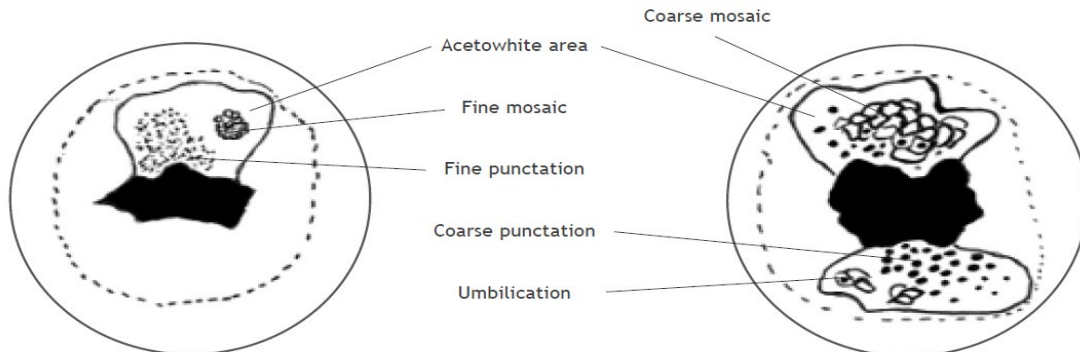
**Fig 4.** The surface contour of high-grade lesion detaches from basal membrane. (source : Massad LS. High-Grade Squamous Intraepithelial Lesions. In: Apgar BS, Brotzman GL, Spitzer M, editors. Colposcopy Principles and Practice - An Integrated Textbook and Atlas. 2nd ed: Elsevier; 2008. p. 231-60).

The contours of the acetowhite area surface of high-grade lesion show nodular, not slippery/flat contour.<sup>2</sup> The Surface contour of the high-grade lesion is easier to detach from basal membrane, causing abrasion in the cervical epithelial. A high-grade lesion shows the contours of an easily peeled surface (*peeling*).<sup>5</sup>

### Vascular pattern and atypical blood vessel

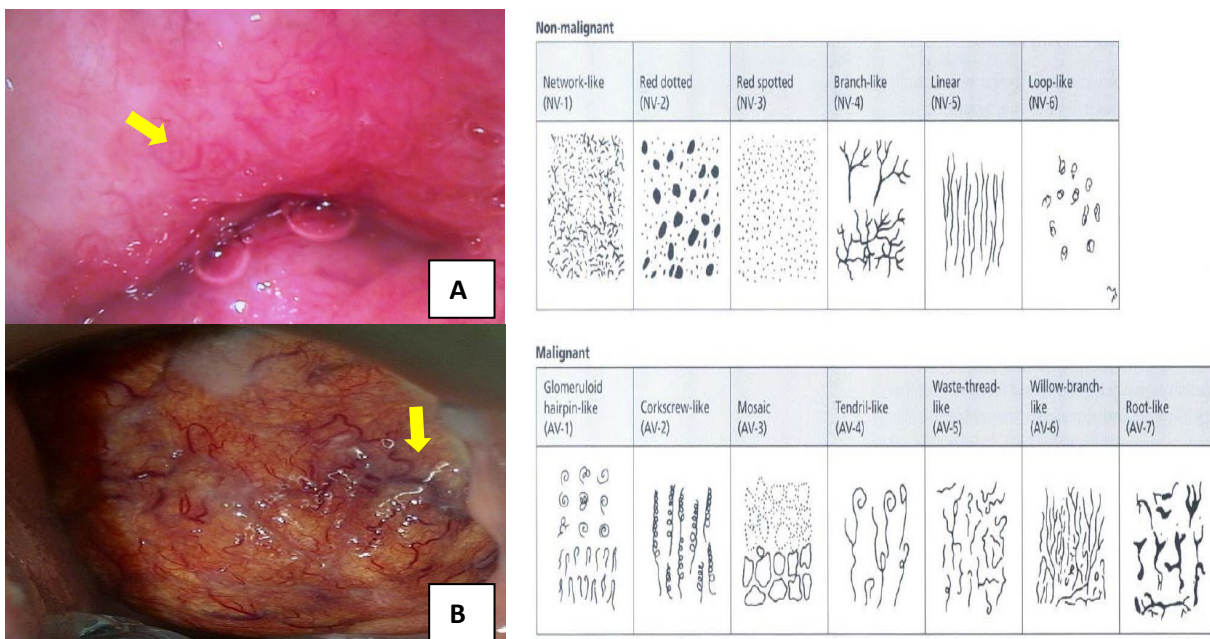
Vascular changes can be clearer by using green filters. In high-grade lesion, we can find a mosaic and a rough (*coarse*) punctation appearance.<sup>5</sup> Abnormal vascular appearance such as punctation and mosaics are only meaningful when inside the acetowhite area.<sup>2</sup> A picture of smooth (*fine*) punctation and mosaic can be found at low-grade lesion.<sup>3</sup> When both of these vascular appearance are welded so that the capillary loops are in the middle of the mosaic image, it is called the *umbilication*.<sup>2</sup>






**Fig 5.** Appearance of mosaics and punctation. source : Singer A, Monaghan JM, Quek SW, Deery ARS. *Diagnosis of Cervical Precancer - The use of colposcopy. Lower Genital Tract Precancer - Colposcopy, Pathology and Treatment. 2nd ed: Wiley-Blackwell; 2000. p. 97-160*

The smaller and smoother the mosaic picture (figure 5), it tends to be a low-grade lesion, while the wider and irregular mosaic appearance then tends to be a high-grade lesion.<sup>3</sup> The farther intercapillary distance, then more rough the vascular pattern.<sup>5</sup> The atypical blood vessels have their own characteristics and are associated with significant pathological changes in the cervical epithelial. Atypical vein is a terminal blood vessel that is described by the irregularities of the shape, calibre and density of blood vessels. The atypical blood vessels can be seen in cervical cancer. There are six forms of atypical blood vessels seen in the precancer lesion (*network-like, red dotted, red spotted, branch like, linear, loop-like*).<sup>1</sup>



**Fig 6.** A. Atypical blood vessel in precancer lesion (branch-like) (yellow arrow). B. Atypical blood vessel in cancer (root-like) (yellow arrow)



eISSN : 2579-8324

pISSN : 2579-8323

**Alamat Korespondensi:**

Ruang Redaksi Andalas Obstetrics and Gynecology Journal, Lantai 3 PPDS Obstetri dan Ginekologi Universitas Andalas, RSUP DR. M. Djamil Padang, Jl. Perintis Kemerdekaan Padang, Sumatera Barat 25127

**Website:**

<http://jurnalobgin.fk.unand.ac.id/index.php/JOE>

**SCORING COLPOSCOPY FINDING**

A large variety of appearance are shown by precancer lesion. The scoring is used to improve the objectivity of the colposcopic finding and reduce variations between the colposcopist. This will reduce subjectivity in assessing a high or low-grade lesion.<sup>1</sup> Scoring should be easy to use in clinical practice, because the purpose of the actual scoring is to assist in the assessment of colposcopy examination whether the conditions are high-grade lesion or low-grade lesion.<sup>9</sup>

**Table 1.** Reid scoring (source Tatti S, Bornstein J, Prendiville W. *Colposcopy: A Global Perspective Introduction of the New IFCPC Colposcopy Terminology. Obstet Gynecol Clin N Am. 2013;40:235-50*)

Colposcopic Sign	0 Points	1 Point	2 Points
Margin	Condylomatous or micropapillary contour	Regular lesions with smooth, straight outlines	Rolled, peeling edges
	Indistinct borders	Sharp peripheral margins	Internal borders between areas of differing appearance
	Flocculated or feathered margins		
	Jagged, angular lesions		
	Satellite lesions, acetowhite change that extends beyond the transformation zone		
Color	Shiny, snow-white color	Shiny, gray-white	Dull, oyster-gray
	Indistinct acetowhite change, semitransparent rather than completely opaque	Intermediate white	
Vessels	Uniform, fine caliber	Absence of surface vessels	Definite punctation or mosaic
	Randomly arranged patterns		Individual vessels dilated, arranged in sharply demarcated, well-defined patterns
	Nondilated capillary loops		
	Ill-defined areas of fine punctation or mosaic		
Iodine staining	Positive iodine uptake, producing a mahogany-brown color	Partial iodine uptake (variegated and tortoiseshell)	Yellow staining of a lesion, which is scored 3/6
	Yellow staining by an area that is recognizable as a low-grade lesion by above criteria (<2/6)		Mustard-yellow appearance
Colposcopic score	0-2 = HPV or CIN 1 (low-grade disease)	3-4 = CIN 1 or CIN 2 (intermediate-grade disease)	5-8 = CIN 2 or CIN 3 (high-grade disease)

Colposcopy terminology that is included in major changes (high-grade lesion) by the *Committee of the International Federation of Cervical Pathology and colposcopy* are strict border, clear internal/demarcation edge, acetowhite obvious depiction of mosaics and rough punctation, and rapid *acetowhite* changes.<sup>8,10</sup> The scoring created by Richard Reid referred as Colposcopy Reid index consists of four finding of colposcopy. The index consists of four variables namely acetowhite color gradation, margin and surface contour lesion, vascular and iodine staining. Each variable has a value of 0-2.<sup>1</sup> If the total score 5-8 will considered as high-grade lesion.



eISSN : 2579-8324

pISSN : 2579-8323

**Alamat Korespondensi:**

Ruang Redaksi Andalas Obstetrics and Gynecology Journal, Lantai 3 PPDS Obstetri dan Ginekologi Universitas Andalas, RSUP DR. M. Djamil Padang, Jl. Perintis Kemerdekaan Padang, Sumatera Barat 25127

**Website:**<http://jurnalobgin.fk.unand.ac.id/index.php/JOE>

**Table 2.** Alternative scoring index. A. Coppleson, B. Swede C. Shafi-Nazeer. (Source : Sellors JW, Sankaranarayanan R (2003), Strander B, Ellstrom-Andersson A, Franzen S, Milsom I, Radberg T. (2005), Nazeer S, Shafi MI (2011).

Grade	Findings		
1. Insignificant	The acetowhite epithelium is usually shiny or semitransparent. The borders are not sharp, with or without fine-calibre vessels (fine punctation and/or fine mosaic), which have ill-defined patterns and short intercapillary distances. There is an absence of atypical vessels.		
2. Significant	Dense acetowhite or grey opaque epithelium is sharply bordered. There are dilated calibre, irregular shaped or coiled vessels (coarse punctation and/or mosaic). Atypical vessels and sometimes irregular surface contour indicate either imminent or invasive cancer.		


  

		0	1	2	Score
A	Aceto uptake	None or transparent	Shady, milky (not transparent not opaque)	Distinct, opaque white	
	Margins/surface	Diffuse	Sharp but irregular, jagged, "geographical" satellites	Sharp and even, difference in surface level including "cuffing"	
	Vessels	Fine, regular	Absent	Coarse or atypical	
	Lesion size	<5 mm	5-15 mm or 2 quadrants	>15 mm or 3-4 quadrants or endocervically undefined	
	Iodine staining	Brown	Faintly or patchy yellow	Distinct yellow	
					Total score

C	Score		
	Zero point	One point	Two points
Index cytology	Low grade	-	High grade
Smoking status	No	-	Yes
Age	≤30 years	>30 years	-
Acetowhitening	Slight	Marked	-
Surface area of lesion	≤1 cm <sup>2</sup>	>1 cm <sup>2</sup>	-
Intercapillary distance	≤350 μ (fine or no mosaic/punctation)	>350 μ (coarse mosaic/punctation)	-
Focality of lesion	Unifocal or multifocal	Annular	-
Surface pattern	Smooth	Irregular	-

As alternative, there is scoring by Coppleson, Swede and Shafi-Nazeer. The Coppleson consist of two criteria (insignificant and significant).<sup>2</sup> The Swede' score uses size of the lesions as one variable. This scoring has a total value of 0 – 10.<sup>4</sup> If the total Swede' score  $\geq 8$  then it has a specificity of 95% to assess a high-grade lesion.<sup>7</sup> The Swede scoring differs from the previous scoring, which does not include the size of the lesions as an important predictor for high degree lesions.<sup>10</sup> The Shafi-Nazeer scoring includes the clinical factors as a variable to determine high-grade lesion. Clinical factors such as age, cytological results (low grade – high grade) and smoking habit are the clinical factors included in this scoring. The picture of the colposcopy assessed on the scoring includes a description of lesions, surface contours, intercapillary distance/vascular pattern, and border area of *acetowhite*.<sup>9</sup>



eISSN : 2579-8324

pISSN : 2579-8323

**Alamat Korespondensi:**

Ruang Redaksi Andalas Obstetrics and Gynecology Journal, Lantai 3 PPDS Obstetri dan Ginekologi Universitas Andalas, RSUP DR. M. Djamil Padang, Jl. Perintis Kemerdekaan Padang, Sumatera Barat 25127

**Website:**

<http://jurnalobgin.fk.unand.ac.id/index.php/JOE>

**CONCLUSION**

1. Colposcopy followed by directional biopsy is the gold standard to diagnose of cervical precancer lesions
2. Three main modalities to diagnose precancer lesions are cytology, colposcopy and histopathology should be interconnected
3. Criteria that distinguish the extent of the high grade compare to low grade are *acetowhite* appearance, demarcation line between the *acetowhite* area with the surrounding area, the blood vessel, and the description of atypical blood vessels
4. Various scoring is available to improve the objectivity of the colposcopic finding and reduce variations between the colposcopist

**REFERENCES**

1. Singer A, Monaghan JM, Quek SW, Deery ARS. Diagnosis of Cervical Precancer - The use of colposcopy. Lower Genital Tract Precancer - Colposcopy, Pathology and Treatment. 2nd ed: Wiley-Blackwell; 2000. p. 97-160.
2. Sellors JW, Sankaranarayanan R. Colposcopic assessment of cervical intraepithelial neoplasia. Colposcopy and Treatment of Cervical Intraepithelial Neoplasia: A Beginners' Manual. 1st ed: WHO-IARC; 2003. p. 55-68.
3. Walker P, Dexeus S, De Palo G, Barrasso R, Campion M, Girardi F, et al. International Terminology of Colposcopy: An Updated Report From the International Federation for Cervical Pathology and Colposcopy. *Obstet Gynecol.* 2003;101(1):175-7.
4. Strander B, Ellstrom-Andersson A, Franzen S, Milsom I, Radberg T. The performance of a new scoring system for colposcopy in detecting high-grade dysplasia in the uterine cervix. *Acta Obstet Gynecol Scand.* 2005;84:1013-7.
5. Massad LS. High-Grade Squamous Intraepithelial Lesions. In: Apgar BS, Brotzman GL, Spitzer M, editors. *Colposcopy Principles and Practice - An Integrated Textbook and Atlas.* 2nd ed: Elsevier; 2008. p. 231-60.
6. O'Connor DM. A Tissue Basis for Colposcopic Findings. In: Rayburn WF, Waxman AG, editors. *Colposcopy, Cervical Screening, and HPV.* 35: *Obstet Gynecol Clin N Am - Elsevier;* 2008. p. 565-82.
7. Bowring J, Strander B, Young M, Evans H, Walker P. The Swede Score: Evaluation of a Scoring System Designed to Improve the Predictive Value of Colposcopy. *J Lower Genit Tract Dis.* 2010;14(4):301-5.
8. Bornstein J, Bentley J, Bösze P, Girardi F, Haefner H, Menton M, et al. 2011 Colposcopic Terminology of the International Federation for Cervical Pathology and Colposcopy. *Obstet Gynecol.* 2012;120:166-72.





eISSN : 2579-8324

pISSN : 2579-8323

## ANDALAS OBSTETRICS AND GYNECOLOGY JOURNAL

**Alamat Korespondensi:**

Ruang Redaksi Andalas Obstetrics and Gynecology Journal, Lantai 3 PPDS Obstetri dan Ginekologi Universitas Andalas, RSUP DR. M. Djamil Padang, Jl. Perintis Kemerdekaan Padang, Sumatera Barat 25127

**Website:**

<http://jurnalobgin.fk.unand.ac.id/index.php/JOE>

9. Nazeer S, Shafi MI. Objective perspective in colposcopy. *Best Practice & Research Clinical Obstetrics and Gynaecology*. 2011;25:631-40.
10. Tatti S, Bornstein J, Prendiville W. Colposcopy: A Global Perspective Introduction of the New IFCPC Colposcopy Terminology. *Obstet Gynecol Clin N Am*. 2013;40:235-50.