



eISSN : 2579-8324

pISSN : 2579-8323

**Alamat Korespondensi:**

Ruang Redaksi Andalas Obstetrics and Gynecology Journal, Lantai 3 PPDS Obstetri dan Ginekologi Universitas Andalas, RSUP DR. M. Djamil Padang, Jl. Perintis Kemerdekaan Padang, Sumatera Barat 25127

**Website:**

<http://jurnalobgin.fk.unand.ac.id/index.php/JOE>

**CASE REPORT****Ectopic Pregnancy With Acceptor Implant**

Putri Zelfitri Zen<sup>1</sup>, Yusrawati<sup>2</sup>

*Affiliations* : 1. Resident of Obstetrics and Gynecology, Faculty of Medicine, Andalas University, Dr. M. Djamil Central General Hospital Padang; 2. Sub Division of Maternal Fetal Medicine, Obstetrics and Gynecology Department, Faculty of Medicine, Andalas University, Dr. M. Djamil Central General Hospital Padang

*Correspondence*: Putri Zelfitri Zen, email : [dr.putrizen@gmail.com](mailto:dr.putrizen@gmail.com), Hp: 085271129393

**Abstract**

**Objective:** To report a case of Ectopic pregnancy with implant receptors

**Materials and Methods:** This article describes the case of a 41-year-old woman, diagnosed with an Ectopic Pregnancy on the gravid G5P4A0H4 11-12 weeks. Patients are using implant contraception, which has been used since 2009-2018 (3 installations). The patient came to the obstetrics and gynecology clinic Dr. M. Djamil Padang. The ultrasound gives the impression of Ectopic pregnancy in the infundibule tube. Analysis Ectopic pregnancy can also occur due to the influence of hormonal contraceptive use (progesterone).

**Results:** Patient gets intervention performed laparotomy After the peritoneum is opened it appears fresh red blood amounting to  $\pm$  500 cc filling the abdominal cavity. Blood evacuation and exploration are performed, it appears that the source of bleeding originates from the left tubal rupture (Infundibulum) Impression of the left tubal rupture (Infundibulum) eectic ectopic pregnancy is impaired. Sinistal salpingectomy was performed.

**Conclusion:** Ectopic pregnancy Ectopic pregnancy is all pregnancies where the ovum fertilized by spermatozoa implant and grows outside the uterine cavity endometrial.

**Keywords:** Ectopic Pregnancy, Acceptor Implant

**INTRODUCTION**

Ectopic pregnancy is any pregnancy in which an egg fertilized by spermatozoa implants and grows outside the endometrium cavity of the uterus.<sup>1</sup> That will put the risk of maternal morbidity and mortality, because rupture and heavy bleeding can occur.<sup>2</sup> Ectopic pregnancies can be divided into several groups, namely occurring in the Tuba (97%), of which 55% appear in the ampullary pars, 25% in isthmus, and 17% in the fimbriae. The remaining 3% are located in the uterus, ovaries, abdominal, and intraligamenter, whereas about 2-2.5% occur in the cornua of the uterus.<sup>3</sup> Cunningham et al<sup>4</sup> divided the risk factors for ectopic pregnancy into high, medium and low risks. High-risk ectopic pregnancy is a history of tubal surgery, history of ectopic pregnancy, use of diethylstilbestrol, history of IUD use and the presence of pathological abnormalities in the tubes. Moderate risk is infertility, infection of genital organs and multiple partners. While the low risk is a history of abdominal or pelvic surgery, smoking, and sexual relations less than 18 years.<sup>5</sup>



eISSN : 2579-8324

pISSN : 2579-8323

**Alamat Korespondensi:**

Ruang Redaksi Andalas Obstetrics and Gynecology Journal, Lantai 3 PPDS Obstetri dan Ginekologi Universitas Andalas, RSUP DR. M. Djamil Padang, Jl. Perintis Kemerdekaan Padang, Sumatera Barat 25127

**Website:**

<http://jurnalobgin.fk.unand.ac.id/index.php/JOE>

Contraception is a measure that helps individuals avoid unwanted pregnancies, get the desired pregnancies, adjust the pregnancy interval, determine the number of children in the family, control the time of birth in relation to the age of the husband and wife. polydemetsilixane) and inserted under the skin which has high effectiveness, and is a long-term contraceptive.<sup>2</sup> The use of contraceptive tools in the form of implants containing progesterone alone is very effective and reversible which works for a long time. This suggests that low progesterin levels, which result in failure to inhibit ovulation and can affect tubal motility and increase the risk of ectopic pregnancy.<sup>3</sup>

**METHOD**

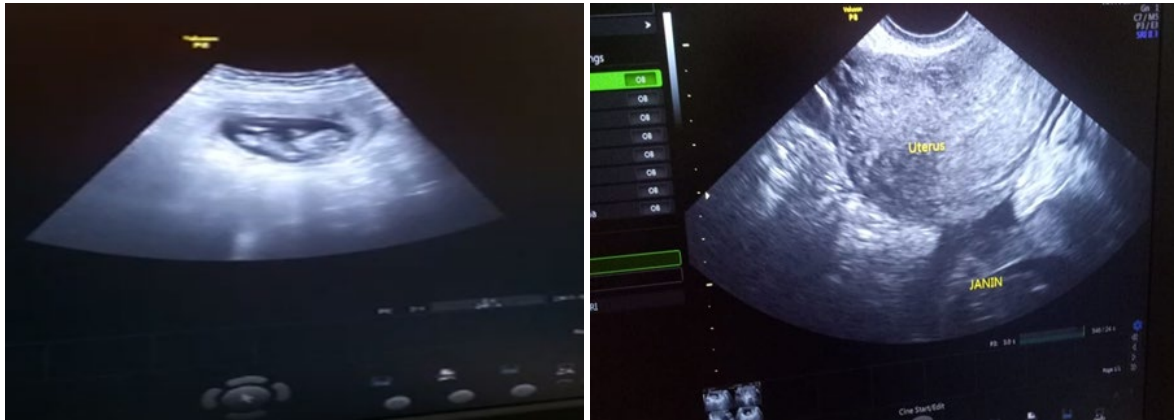This article describes a case report of a 41 year old woman diagnosed with ectopic pregnancy at 11-12 weeks of gravid G5P4A0H4. The patient is currently using implant contraceptives, which have been used since 2009-2018 (3 installations). The patient came to the obstetrics and gynecology Polyclinic of Dr. M. Djamil Padang. The ultrasound examination gives the impression of an ectopic pregnancy in infundibulum tube. Analysis Ectopic pregnancy can also occur due to the influence of the use of hormonal contraceptives (progesterone).

**CASE REPORT**

A 41 year old female patient, diagnosed with ectopic pregnancy at 11-12 weeks of gravid G5P4A0H4. The patient previously complained of pain in the placenta accompanied by slight discharge from the genitals. the patient did not realize that she was pregnant, because the patient claimed to be using implant contraceptives, from 2009-2018.

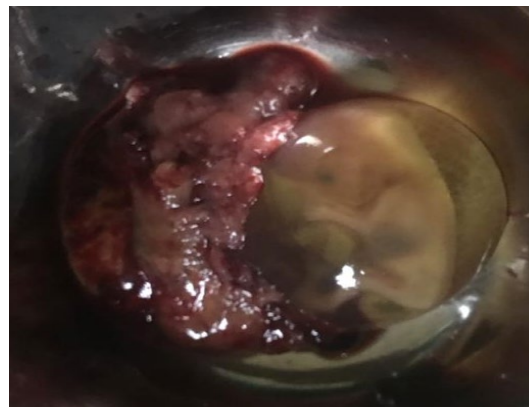
Physical examination found anemic conjunctiva (-/-), tenderness in the lower abdomen. The results of deep examination with Vagi al touche (VT) showed negative pain shaking the portio.

Then the culdosynthesis examination was carried out with the result (-). After being suspected of having an ectopic pregnancy, abdominal ultrasound and laboratory investigations were performed. Positive pregnancy test. On ultrasound examination found Uterus AF measuring 6.42 cm x 3.79 cm x 4.22 cm. Extra uterine GS visible, CRL 4.15cm according to 11-12 weeks gestation, FHR (+). No intra-abdominal free fluid was seen. The ultrasound examination gives the impression of an ectopic pregnancy in infundibulum tube. Analysis Ectopic pregnancy can also occur due to the influence of the use of hormonal contraceptives (progesterone) which can affect the work of cilia in the fallopian tubes.



**Figure 1.** (a) Extra uterine fetus, (b) Uterus


A laparotomy was performed. After opening the peritoneum,  $\pm$  500 cc of fresh red blood appeared to fill the abdominal cavity. Blood evacuation and exploration were carried out, it appears that the source of bleeding comes from the left tubal rupture (infundibulum). A left salpingectomy was performed.



**Figure 2.** Results of conception

## DISCUSSION

A case of ectopic pregnancy with an implant acceptor has been reported. The diagnosis is confirmed by careful physical, laboratory and ultrasound examination. Based on these tests, laboratory results obtained positive pregnancy tests and ultrasound examination found the AF uterus measuring 6.42 cm x 3.79 cm x 4.22 cm. +). No intra-abdominal free fluid was seen. The ultrasound examination gives the impression of Ectopic pregnancy. Ectopic pregnancy is also known as a tubal pregnancy, where this pregnancy usually occurs along the tube that carries an egg from the ovary to the uterus (fallopian tube). Ectopic pregnancies occurred most frequently in the Tuba (97%), of which 55% appeared in the ampullary pars, 25% in the isthmus, and 17% in the fimbriae. The remaining 3% are located in the uterus, ovaries,



eISSN : 2579-8324

pISSN : 2579-8323


**Alamat Korespondensi:**

Ruang Redaksi Andalas Obstetrics and Gynecology Journal, Lantai 3 PPDS Obstetri dan Ginekologi Universitas Andalas, RSUP DR. M. Djamil Padang, Jl. Perintis Kemerdekaan Padang, Sumatera Barat 25127

**Website:**

<http://jurnalobgin.fk.unand.ac.id/index.php/JOE>

abdominal, and intraligamentary, whereas about 2-2.5% occur in the cornua of the uterus.<sup>3</sup> The fallopian tube or what is known as the oviduct is a tube that connects the ovary to the uterus and serves as a transportation route for the ovum from the ovary to the uterus. The fallopian tube consists of a pair found on the left and right of the uterus, with a length of 10-13 cm, and a diameter of 0.5-1.2 cm. The tubal wall consists of 4 layers, namely the serous layer (outermost layer), the subserous layer / muscle layer which consists of blood vessels, lymphatic vessels, longitudinal muscles and circular muscles. The muscles in this layer function to create movement so that the fallopian tubes can transport the ovum from the ovary to the uterus. Lamina propria layer, most of this layer is blood vessels so it is often called the vascular layer. Mucosa layer, this layer is composed of ciliated columnar epithelium and secretory cells. The fallopian tubes perform their functions through peristaltic contractions (pushing movements) of the smooth muscle fibers in the walls of the tubes. At the time of fertilization, spermatozoa move rapidly into the fallopian tubes. This movement is caused by contractions of the uterine muscles in the tubes. While the fertilized ovum immediately divides while moving, assisted by cilia in the fallopian tube to the uterus, then attaches to the uterine mucosa, then implants in the uterine cavity. This movement is mainly regulated by the three intrinsic systems, namely the estrogen-progesterone hormonal environment, the adrenergic-nonadrenergic system. Estrogens act on receptors stimulating tubal motility, whereas progesterone, which activates  $\beta$  receptors, inhibits tubal motility. Prior to ovulation, the contractions are gentle, with some individual variation in rate and pattern. At ovulation, the contractions become strong and the rhythmic fimbria work to sweep over the surface of the ovary. Progesterone levels increase 4-6 days after ovulation, inhibiting tubal motility. This can cause relaxation of the fallopian muscles to allow part of the egg into the uterus by the action of the tubal cilia. The effects of estrogen and progesterone on oviductal motility and morphology are mediated via these steroid receptors. Changes in the receptor level are very important in determining the functional state of the oviduct. Adrenergic innervations are thought to be involved in the regulation of tubal motility, particularly changes in isthmic motility. During the menstrual and proliferative (preovulatory) phases, the human tube is very sensitive to adrenergic compounds such as norepinephrine. After ovulation and during the luteal phase, the response to norepinephrine decreases and the inhibitory effect of adrenergic compound  $\beta$  is more pronounced. Estrogen potentiates the activation of the receptor, whereas progesterone potentiates the activation of the  $\beta$  receptor. Activation of the receptors by raised levels of progesterone in the luteal phase causes relaxation of the circular muscles; thus, the isthmic luminal diameter increases and the transisthmic portion of the fertilized ovum is facilitated. Although there is controversy regarding the role of prostaglandins in the regulation of spontaneous tubal motility, it has been found that prostaglandin F<sub>2</sub> (a PGF<sub>2</sub> a) stimulates whereas PGE<sub>1</sub> and PGE<sub>2</sub> inhibits oviduct contractions.



eISSN : 2579-8324

pISSN : 2579-8323

**Alamat Korespondensi:**

Ruang Redaksi Andalas Obstetrics and Gynecology Journal, Lantai 3 PPDS Obstetri dan Ginekologi Universitas Andalas, RSUP DR. M. Djamil Padang, Jl. Perintis Kemerdekaan Padang, Sumatera Barat 25127

**Website:**

<http://jurnalobgin.fk.unand.ac.id/index.php/JOE>

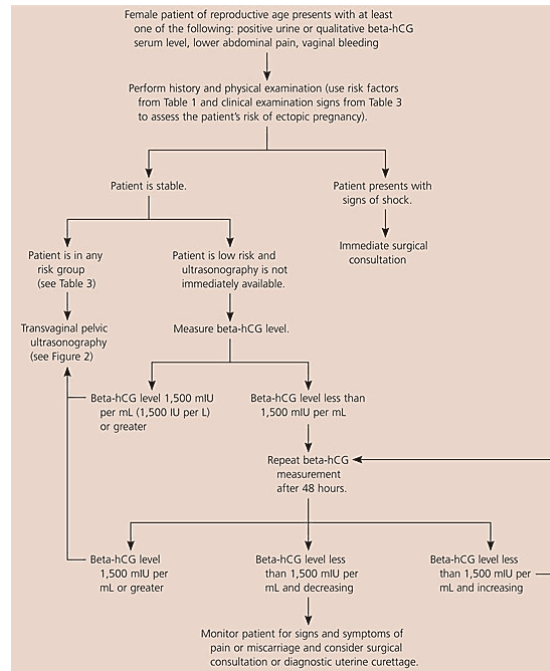
Contrary to their differential activity on tubal motility, all three natural prostaglandins (PGF<sub>2</sub>, PGE<sub>1</sub>, and PGE<sub>2</sub>) stimulate cilia activity in vitro. In summary, the initial rise in progesterone after ovulation causes b-mediated contraction of the two inner layers of the uterotubal junction, thereby leading to locking of the ovary tubes. After a few days, the sensitivity of the muscle to adrenergic stimulation decreases, while other factors, such as prostaglandins, predominate causing relaxation of the utero tubal junction and release of the fertilized ovum into the uterine cavity. To diagnose an ectopic pregnancy can be done by checking B-HCG levels and checking progesterone levels that have decreased.<sup>6</sup> In this case, implant contraceptives are used, where implant contraception is a form of contraceptive in the form of a silastic capsule containing a progestin-type hormone (progesterone only) which is placed under the skin.<sup>7</sup> Progesterone is a steroid hormone secreted by the corpus luteum, placenta and a small number of follicles. Progesterone, like other steroid hormones, is synthesized from pregnolone, a cholesterol derivative. Together with estrogen plays an important role in the regulation of female hormones. Progesterone also plays a role in the reproductive organs including the mammary gland and the endometrium as well as the increase in human body temperature. Another progesterone target organ is the uterus, where it assists with ovum implantation. During pregnancy progesterone retains the placenta, inhibiting uterine contractility.<sup>1</sup> The hormone progesterone can increase ectopic pregnancy because progesterone interferes with the movement of the cilia in the fallopian tubes that carry the fertilized egg to implant into the uterus.<sup>8</sup>

One of the effective contraceptives is implants or better known as implant KB, since 1981 it has been developed in Indonesia and until now. In various worlds implants have been used by more than 10 thousand women. An implant is a contraceptive device that is inserted under the skin of the inner upper arm, in the form of a silastic (flexible) capsule where in each capsule contains the hormone progesterone which can prevent pregnancy. lenders the cervix and thins the lining of the endometrium.<sup>7</sup>

However, the use of spiral contraceptives and hormone (progesterone) can lead to ectopic pregnancy. Because progesterone can interfere with the movement of cilia hair cells in the fallopian tubes that carry a fertilized egg to implant into the uterus. When the progesterone hormone increases in the body, the body will experience changes. The nature of the progesterone hormone is to temporarily inhibit myoelectrical activity and provide relaxation to smooth muscle work, including reducing the ability of cilia in the area of the fallopian tubes to transport the fertilized zygote ovum into the implanted uterine cavity.

In this case, the patient presented with complaints of abdominal pain, but did not experience vaginal bleeding and vital signs were still within normal limits. In ectopic pregnancy the signs that we should be aware of are recurrent abdominal pain, nausea, vomiting, which occurs in the second and third trimesters, vaginal bleeding. From physical

examination, vital signs must be considered because this can be a marker if there is bleeding which will cause disrupted ectopic pregnancy.<sup>9</sup>



**Figure 1.** Pathways used to diagnose a suspected ectopic pregnancy

## CONCLUSION

An ectopic pregnancy is any pregnancy in which an egg fertilized by spermatozoa implants and grows outside the endometrium cavity of the uterus. Based on the site of implantation, the fallopian tube is the most common site for ectopic pregnancy implantation, rarely implantation of the ovaries, abdominal cavity, uterine cervical canal, rudimentary uterine horns and uterine diverticles. Implant contraception is a subdermal insertion of contraceptive method containing only a long-acting, low-dose, reversible progestin for women. Careful prenatal examination is needed in making the diagnosis. This reported case is a case of KE with implant acceptor based on clinical findings, USG.

## REFERENCES

1. Abdulkareem T A, Eidan S M. Ectopic Pregnancy: Diagnosis, Prevention and Management. Intech journal. 2017.
2. Prawirohardjo, Sarwono. Ilmu Kebidanan. 2014. Bina Pustaka Sarwono Prawirohardjo. Jakarta



eISSN : 2579-8324

pISSN : 2579-8323

## ANDALAS OBSTETRICS AND GYNECOLOGY JOURNAL

**Alamat Korespondensi:**

Ruang Redaksi Andalas Obstetrics and Gynecology Journal, Lantai 3 PPDS Obstetri dan Ginekologi Universitas Andalas, RSUP DR. M. Djamil Padang, Jl. Perintis Kemerdekaan Padang, Sumatera Barat 25127

**Website:**

<http://jurnalobgin.fk.unand.ac.id/index.php/JOE>

3. Alagbe O A, Adeniyi T O, Olawale Abayomi A, Onifade E O. Interstitial ectopic pregnancy: a case report. *Pan African Medical Journal*. 2017; 28:135 doi:10.11604/pamj.2017.28.135.13889
4. Cunningham, F. Gary. 2014. *Obstetri Williams*. Ed. 24. Jakarta: EGC
5. Green-top Guideline No. 21. 2016. *Diagnosis and Management of Ectopic Pregnancy*. Royal College of Obstetricians and Gynaecologists.
6. Gaddagi AR, Chandrashekhar AP. A Clinical Study of Ectopic Pregnancy. *Journal of Clinical and Diagnostic Research*. 2012 June, Vol-6(5): 867-869.
7. Buku acuan Pelayanan Kontrasepsi dan Keluarga Berencana. BKKBN.2018
8. Brüggmann D, Kollascheck J, Quarcoo D, Bendels M H, Klingelhöfer D, Louwen F, Jaque J M, Groneberg D A. Ectopic pregnancy: exploration of its global research architecture using density-equalising mapping and socioeconomic benchmarks. *BMJ Open*. 2017
9. Sepilian VP, Wood E. Ectopic pregnancy [internet]. New York: Medscape; 2015