

eISSN : 2579-8324

pISSN : 2579-8323

CASE REPORT

Omphalocele

Revivo Rinda Pratama¹, Roza Sri Yanti²

Affiliations : 1. *Obstetrics and Gynecology Department, Dr. M. Djamil Central General Hospital Padang, West Sumatera, Indonesia*; 2. *Sub Division of Fetomaternal Medicine, Obstetrics and Gynecology Department, Faculty of Medicine, Andalas University, Dr. M. Djamil Central General Hospital Padang, West Sumatera, Indonesia*

Correspondence: Revivo Rinda Pratama, email : dr.revivorinda@gmail.com, Hp: 082285353450

Abstract

Objective: Reporting a case of omphalocele.

Method: Case report.

Result: A case of a 32 years-old woman, diagnosed with G2P1A0H1 34-35 weeks of preterm pregnancy + previous Cesarean Section + omphalocele + fetal distress. According to ultrasonography, biometric measurements of the fetus were: BPD: 8.5 cm, FL: 6.4 cm, HL: 5.2 cm, AC: 27.8 cm, AFI: 23.3 cm, there were no image of abdominal wall, but a membrane surrounding the abdomen was visible. From the USG examination, the conclusion was Omphalocele. Chromosomal analysis was done using G-Comparative technic, with result 46, XY, which means the amount of the chromosomes was 46, and sex chromosomes were XY. There was no major structural defect. Mostly, the disorders causing these conditions are 13, 18 and 21 trisomy, and Beckwith-Wiedemann Syndrome.

Conclusion: Omphalocele is a genetic disorder marked by failure of the abdominal organs to return into the abdominal cavity. It requires thorough and accurate prenatal examinations to establish a diagnosis.

Keywords: Omphalocele, prenatal diagnosis

INTRODUCTION

Omphalocele is a defect of the abdominal wall in the insertion of the umbilical cord with intestinal herniation or other contents of the abdominal cavity wrapped in a membrane / membrane. One other abdominal wall defect is gastroschisis, which is if the herniated organ is not covered by any membrane. Initially intestinal and other abdominal organs develop outside the abdomen and will return to the abdominal cavity at 10-12 weeks. But in patients with omphalocele the process of return to the abdominal cavity does not occur perfectly. Organs that do not return to the abdominal cavity are covered by a membrane / membrane.^{1,2} Omphalocele is a defect abdominal wall is most often found, which is about 1.92 per 10,000 live births. Newborns with omphalocele more male sex and born to mothers aged 35 years and over or 20 years and under. Infants with omphalocele are usually accompanied by other congenital abnormalities such as cardiac abnormalities (32%). In addition, omphalocele is also associated with chromosomal abnormalities, especially trisomy 13, 18, and 21, which are found in about 20-50% of cases, and often cause fetal death. The survival rate of isolated

omphalocele (without comorbid or chromosomal abnormalities) is 96%, and this number drops dramatically when accompanied by other anomalies or abnormal karyotypes. Infant mortality (28.7%) which usually occurs within the first 28 days of life.^{1,2}

The exact mechanism of the occurrence of omphalocele is still not fully explained. The abdominal wall is formed through the fusion of four plates, namely cephalic plates that form the thoracic wall and the epigastric part of the abdomen; caudal plates that form the perineum, bladder and hypogastric region; and two side plates that form the lateral sides of the abdomen.

The four meet in the middle and fused to form the umbilic ring in the 4th week. The primitive intestine undergoes rapid enlargement in the 6th week, which causes herniation of the umbilical ring and then goes through a process of rotation and reintegration in the 10th week. Abdominal wall defects are thought to be due to early disruption in the process of mesenchymal differentiation due to something not yet known.

Omphalocele can be diagnosed prenatally by ultrasound examination. Return of the intestine after physiological herniation at 10 weeks can be confirmed by ultrasonography in the 11th to 14th week together with nuchal translucency screening for Down's Syndrome.⁴

CASE REPORT

A 32-year-old female patient, with a diagnosis with G2P1A0H1 34-35 weeks of preterm pregnancy + previous cesarean section + omphalocele + fetal distress. On ultrasound examination at 25 weeks gestation, fetal biometry was found; BPD: 64,6 mm, FL: 45,4 mm, HL: 42,7 mm, AC: 162,1 mm, AFI: 14,3 cm, protruding mass appears on the anterior abdominal wall with size of omphalocele sac 5,06 x 3,26 cm

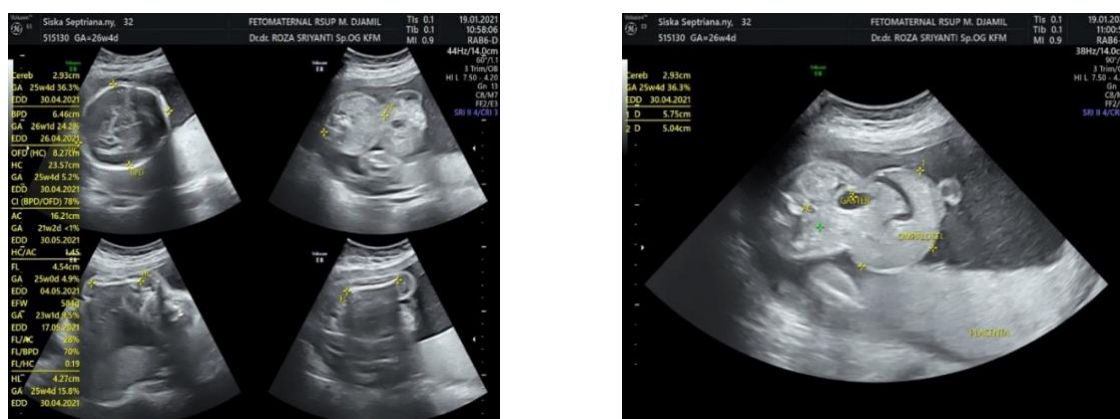

Figure 1. (a) Omphalocele mass, (b) Fetal biometry

Chromosome Analysis Test carried out by the G-Banding technique has been studied chromosomes from 20 cells and get the number of chromosomes in each cell studied is 46, XY. Which means the number of chromosomes is 46 units with the patient's sex chromosome is XY. No major structural abnormalities appear.

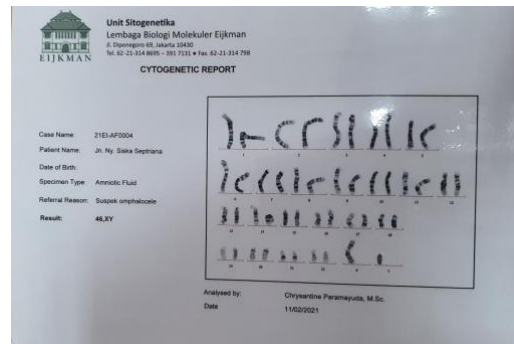


Figure 2. Chromosome 46, XY

Born baby boy, body weight 1600 gr, body length 40 cm, AS 5/6, visible contents of the abdominal cavity wrapped in protruding membranes from the abdomen (omphalocele).

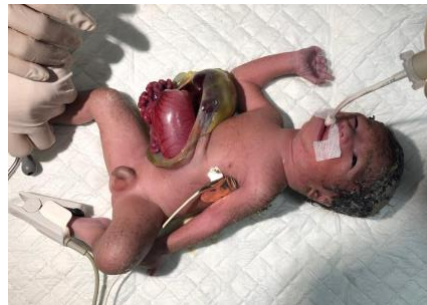

Figure 3. Omphalocele


DISCUSSION

An Omphalocele case was reported. The diagnosis is made by careful and repeated antenatal ultrasound examination. Based on this last examination fetal biometry results were obtained; BPD: 85,4 mm, FL: 64 mm, HL: 52,2 mm, AC: 278 mm, AFI: 23,3 cm, visible mass protruding out of the anterior abdominal wall.

In some of the literature mentioned that prenatal diagnosis can be done by ultrasound examination.^{1,6,10} On this examination it can be found: the appearance of a mass with a sharp border protruding out of the anterior wall abdomen and sometimes accompanied by polyhydramnios.^{2,5}

In this case, the antenatal ultrasound results were consistent with the image of an omphalocele patient in which a well-defined mass protruded from the surface of the anterior abdominal wall.^{7,8} The basis of the defect usually comes from the insertion of the umbilical cord.⁹ Herniation of intra-abdominal organs usually consists of intestines sometimes accompanied by other organs.¹¹

The chromosome analysis test was performed using the G-Banding technique.¹² The chromosomes of 20 cells were studied and the chromosome number in each cell studied was 46, XY. Which means the number of chromosomes is 46 with the patient's sex chromosome is XY. No major structural abnormalities were seen.^{13,14}



eISSN : 2579-8324

pISSN : 2579-8323

Address for Correspondence:Editorial Room Andalas Obstetrics and Gynecology Journal, 3rd floor of KSM of Obstetrics and Gynecology, RSUP DR. M. Djamil Padang, Jl. Perintis Kemerdekaan Padang, Sumatera Barat 25127**Website:**<http://jurnalobgin.fk.unand.ac.id/index.php/JOE>

However, there are several chromosomal abnormalities that usually accompany omphalocele events, the most common being trisomy 13, 18 and 21 and with Beckwith-Wiedemann Syndrome.^{2,15} In addition there are several other chromosomal abnormalities that are rare, namely, Turner syndrome, Klinefelter syndrome and Pallister-killian syndrome.⁵

Another examination that can be done while the patient is antenatal control is MRI.¹⁶ In contrast to ultrasound which is highly operator dependent, MRI is not.^{5,17} The field of view obtained from MRI is also broader than that obtained through ultrasound examination. A wide field of view will provide a good anatomical orientation. MRI was also unaffected by maternal obesity and oligohydramnios. However, fetal motion can affect MRI.⁵

If a case of omphalocele was diagnosed before delivery, carry out a thorough examination to check for other congenital abnormalities.¹⁸ The choice for termination of pregnancy in this patient is cesarean section. The cesarean section was chosen to avoid trauma during the delivery process of the omphalocele mass, because if the delivery is done vaginally, when the baby is born where there is an omphalocele mass, labor will be obstructed and if it is forced it can result in injury or trauma to the omphalocele mass itself.⁵ After the baby is born, the possibility of other congenital abnormalities such as heart defects (occurs in 50% of cases), central nervous system disorders, urogenitalia (bladder exstrophy, cloacal exstrophy) and skeletal abnormalities is not found. other comorbidities in infants.¹⁹ Furthermore, this baby has also been performed three times by the pediatric surgery department, namely, two operations for the treatment of hernias and one operation to close the omphalocele defect.²⁰

CONCLUSION

Omphalocele is a defect of the abdominal wall in the insertion of the umbilical cord with herniation of the intestine or other contents of the abdominal cavity that are covered with a membrane / membrane. The prenatal diagnosis of omphalocele can be confirmed by ultrasound examination. It takes collaboration from multidisciplinary science for handling the baby.

REFERENCES

1. Kleinrouweler C, Kuijper C, van Zalen-Sprock M, Mathijssen I, Bilardo C, Pajkrt E. Characteristics and Outcome and the Omphalocele Circumference/Abdominal Circumference Ratio in Prenatally Diagnosed Fetal Omphalocele. *Fetal Diagnosis and Therapy*. 2011;30(1):60-69.
2. Butt S, Khadija S, Amir Gilani S. A Report on Prenatal Diagnosis of a Rare Case of Fetal Acrania and Omphalocele by Doppler Examination. *Journal of Radiology and Clinical Imaging*. 2020;03(01).
3. Nonaka A, Hidaka N, Kido S, Fukushima K, Kato K. Prenatal imaging of a fetus with the rare combination of a right congenital diaphragmatic hernia and a giant omphalocele.



eISSN : 2579-8324

pISSN : 2579-8323

Address for Correspondence:Editorial Room Andalas Obstetrics and Gynecology Journal, 3rd floor of KSM of Obstetrics and Gynecology, RSUP DR. M. Djamil Padang, Jl. Perintis Kemerdekaan Padang, Sumatera Barat 25127**Website:**<http://jurnalobgin.fk.unand.ac.id/index.php/JOE>**Congenital Anomalies. 2014**

4. Poaty, H., Pelluard, F., Diallo, M.S. *et al.* Omphalocele: a review of common genetic etiologies. *Egypt J Med Hum Genet* 2019 : **20**, 37
5. Waghmare TP, Sathe PA, Goel NA, Kandalkar BM (2016) Alobar holoprosencephaly associated with meningomyelocele and omphalocele: an unusual coexistence. *J Clin Diagn Res* 10:ED23–ED24
6. Roux N, Grangé G, Salomon LJ, Rousseau V, Khen-Dunlop N, Beaudoin S (2019) Early diagnosis of omphalocele: prognostic value of the herniated viscera for associated anomalies. *Gynecol Obstet Fertil Senol* 47:637–642
7. Watanabe S, Suzuki T, Hara F, Yasui T, Uga N, Naoe A (2017) Omphalocele and gastroschisis in newborns: over 16 years of experience from a single clinic. *J Neonat Surg* 6:27
8. Zhou HF, O’Conor CJ, Gangahar C, Dehner LP (2018) 15q23 Gain in a neonate with a giant omphalocele and multiple co-occurring anomalies. *Case Rep Pediatr* 2018:8702568
9. Ogata T, Kagami M (2016) Kagami-Ogata syndrome: a clinically recognizable upd(14)pat and related disorder affecting the chromosome 14q32.2 imprinted region. *J Hum Genet* 61:87–94
10. Swarray-Deen A, Seffah JD, Antwi-Agyei DA (2017) Two cases of pentalogy of Cantrell diagnosed antenatally at Korle Bu Teaching Hospital, Accra. *Ghana Med J* 51:191–195
11. Bastaki F, Saif F, Al Ali MT, Hamzeh AR (2016) Molecular and clinical characterization of a nonsense *CDKN1C* mutation in an Emirati patient with Beckwith-Wiedemann syndrome. *Saudi Med J* 37:215–216
12. Omid AAM, Hellè M, Oumarou H, Karim CMA (2017) Abarchi Habibou Les Pathologies Chirurgicales Néonatales À l’Hôpital National De Lamordé De Niamey: Aspects diagnostiques, thérapeutiques et pronostiques. *Eur Sci J* 13:1857–7431
13. Mills JL, Carter TC, Kay DM, Browne ML, Brody LC, Liu A, Romitti PA, Caggana M, Druschel CM (2012) Folate and vitamin B12-related genes and risk for omphalocele. *Hum Genet* 131:739–746
14. Hijkoop A, Peters NCJ, Lechner RL, van Bever Y, van Gils-Frijters APJM, Tibboel D, Wijnen RMH, Cohen-Overbeek TE, IJsselstijn H. Omphalocele: from diagnosis to growth and development at 2 years of age. *Arch Dis Child Fetal Neonatal Ed.* 2019 Jan;104(1):F18-F23.
15. Barisic I, Boban L, Akhmedzhanova D, Bergman JEH, Cavero-Carbonell C, Grinfelde I, Materna-Kiryluk A, Latos-Bieleńska A, Randrianaivo H, Zymak-Zakutnya N, Sansovic I, Lanzoni M, Morris JK. Beckwith Wiedemann syndrome: A population-based study on prevalence, prenatal diagnosis, associated anomalies and survival in Europe. *Eur J Med Genet.* 2018 Sep;61(9):499-507.
16. Brioude F, Hennekam R, Bliet J, Coze C, Eggermann T, Ferrero GB, Kratz C, Bouc YL, Maas SM, Mackay DJG, Maher ER, Mussa A, Netchine I. Revisiting Wilms tumour surveillance



- in Beckwith-Wiedemann syndrome with IC2 methylation loss, reply. *Eur J Hum Genet.* 2018 Apr;26(4):471-472
17. Karaman A, Aydin H, Göksu K. Concomitant omphalocele, anencephaly and arthrogyposis associated with trisomy 18. *Genet Couns.* 2015;26(1):77-9.
 18. Sundgren NC, Kelly FC, Weber EM, Moore ML, Gokulakrishnan G, Hagan JL, Brand MC, Gallegos JO, Levy BE, Fortunov RM. Improving communication between obstetric and neonatology teams for high-risk deliveries: a quality improvement project. *BMJ Open Qual.* 2017;6(2):e000095.
 19. Conner P, Vejde JH, Burgos CM. Accuracy and impact of prenatal diagnosis in infants with omphalocele. *Pediatr Surg Int.* 2018 Jun;34(6):629-633
 20. Kirby RS. The prevalence of selected major birth defects in the United States. *Semin Perinatol.* 2017 Oct;41(6):338-344.