

eISSN : 2579-8324

pISSN : 2579-8323

Address for CorrespondenceEditorial Room Andalas Obstetrics and Gynecology Journal, 3rd floor of KSM of Obstetrics and Gynecology, RSUP DR. M. Djamil Padang, Jl. Perintis Kemerdekaan Padang, Sumatera Barat 25127**Website:**<http://jurnalobgin.fk.unand.ac.id/index.php/JOE>**CASE REPORT****Placenta Percreta With Bladder Infiltration : A Case Report**Bayu Permana¹, Syahredi²

Affiliation: 1. Obstetrics and Gynecology, Faculty of Medicine, Andalas University, Dr. M. Djamil Central General Hospital Padang; 2. Sub Division of Social Obstetrics and Gynecology, Obstetrics and Gynecology Department, Faculty of Medicine, Andalas University, Dr. M. Djamil Central General Hospital Padang

Correspondence: Bayu Permana, email: bayupermanapiliang@gmail.com, Hp: 081273861239

Abstract

Objective : To report a case of placenta percreta with bladder infiltration.

Method : Case reports.

Case : a 24-year-old female G2P1A0H1 gravid 26-27 weeks, placenta percreta with gross hematuria. The second pregnant patient was less months pregnant with the results of a fetal ultrasound examination with a placenta covering the uterine internum (OUI) and suspected of penetrating the uterine wall (percreta), and a cesarean hysterectomy was performed.

Discussion : The cause of placenta percreta is unknown, it is associated with several clinical risk factors like the previous cesarean, placenta previa, grand multiparity, and previous uterine curettage. The management of placenta percreta can be challenging because the loss occurs at two sites in labor. Refractory hematuria occurs in 25% of patients due to placenta percreta invasion of the bladder. Management involves a team of obstetricians, urologists, intensivists, and neonatologists. Treatment is preferably carried out in tertiary care where there is a definite stock of blood with adequate blood products, a fully equipped neonatal intensive care unit (NICU). Delivery may be considered at 34-35 weeks gestation if there is no maternal and fetal deterioration because the incidence of antepartum hemorrhage appears to increase sharply at 36 weeks.

Conclusion : Management is recommended for placenta percreta cases, planning for premature cesarean hysterectomy with placenta left in situ. However, the diagnosis is made based on the results of the anatomic pathology obtained after hysterectomy, and is not considered a first-line treatment for women who still wish to maintain future fertility.

Keywords: placenta percreta, cesarean hysterectomy

INTRODUCTION

Abnormal placental adherence can be classified into three distinct conditions: placenta accreta, in which placental tissue invades the decidual surface of the myometrium; placenta increta, in which placental villi invade more deeply within the myometrium, and placenta percreta where chorionic villi penetrate through the uterine serosa and may invade surrounding organs such as the bladder.^{1,2} It results from the abnormal attachment of the placental villi to the myometrium instead of the intervening decidua. This includes placenta

Address for Correspondence

Editorial Room Andalas Obstetrics and Gynecology Journal, 3rd floor of KSM of Obstetrics and Gynecology, RSUP DR. M. Djamil Padang, Jl. Perintis Kemerdekaan Padang, Sumatera Barat 25127

Website:

<http://jurnalobgin.fk.unand.ac.id/index.php/JOE>

accreta (75%–78%) in which placental chorionic villi invade only superficial myometrium, placenta increta (17%–18%) where placental chorionic villi invade more than half of the myometrium, and, very rarely, placenta percreta (5%) where chorionic villi invade through the myometrium, serosa, and occasionally into adjacent organs such as the bladder.²⁻⁵ Massive hematuria resulting from placental infiltration into the bladder presents with maternal and fetal life-threatening hematuria if operative action is not performed. We report a case of a patient with placenta percreta and bladder invasion who should undergo immediate operative action.^{1,6,7}

CASE REPORT

Presented a case of placenta percreta with gross hematuria in a patient aged 24 years. This is the second pregnancy with one cesarean delivery. Not having regular antenatal screening. at 26-27 weeks of gestation there are complaints of reddish urination without pain. The result of ultrasound examination shows that the placenta is implanted in the anterior corpus that extends into OUI with bridging vessels in the lining of the bladder. Results of hemoglobin 8.8 gr / dL, macroscopic urinalysis of 500-600 HPF erythrocytes. an elective cystoscopy was planned but due to a drastic decrease in hemoglobin it was decided to do emergency cesarean delivery.

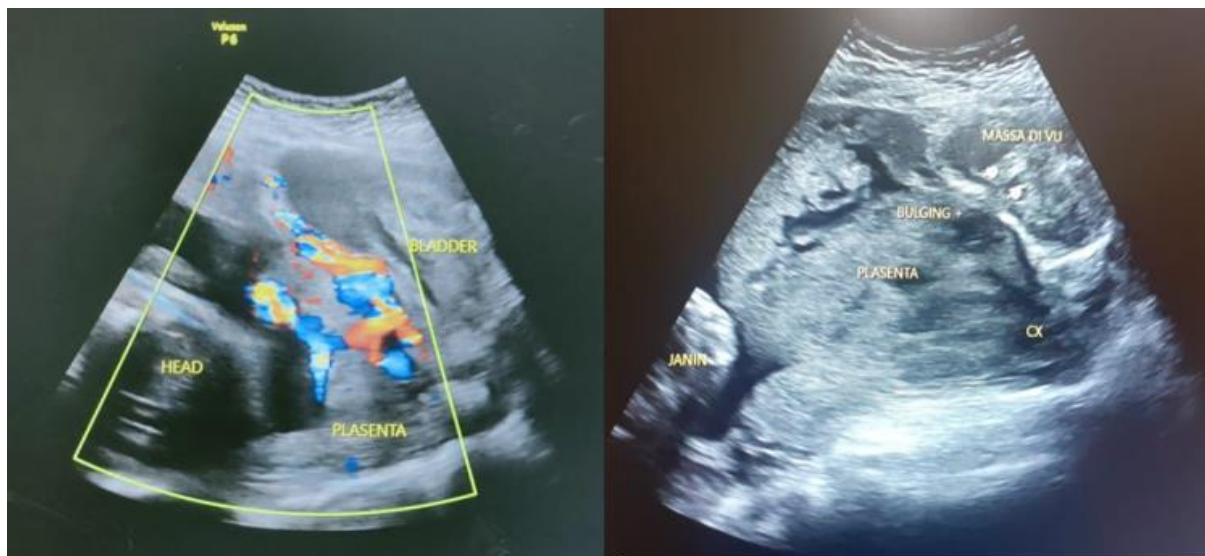


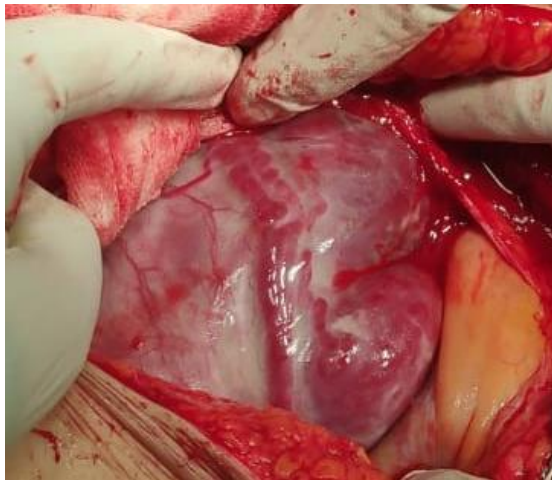
Figure 1. Abdominal ultrasound of placenta infiltration to bladder

Address for Correspondence

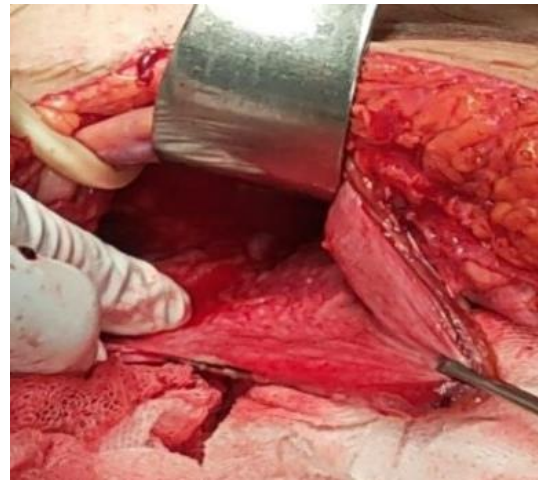
Editorial Room Andalas Obstetrics and Gynecology Journal, 3rd floor of KSM of Obstetrics and Gynecology, RSUP DR. M. Djamil Padang, Jl. Perintis Kemerdekaan Padang, Sumatera Barat 25127

Website:

<http://jurnalobgin.fk.unand.ac.id/index.php/JOE>



2A




2B

Figure 2. A. Placenta vessels appear on the surface of the uterus; B. the part of the placenta that penetrates the bladder

DISCUSSION

The cause of placenta percreta is unknown, it is associated with several clinical risk factors like the previous cesarean, placenta previa, grand multiparity, and previous uterine curettage. The management of placenta percreta can be challenging because the loss occurs at two sites in labor.^{3-6,9} Refractory hematuria occurs in 25% of patients due to placenta percreta invasion of the bladder. Management involves a team of obstetricians, urologists, intensivists, and neonatologists.^{3-7,9} Treatment is preferably carried out in tertiary care where there is a definite stock of blood with adequate blood products, a fully equipped neonatal intensive care unit (NICU).^{1,3,4,7,8} Delivery may be considered at 34-35 weeks' gestation if there is no maternal and fetal deterioration because the incidence of antepartum hemorrhage appears to increase sharply at 36 weeks.⁸⁻¹⁰

Placenta accreta occurs in about 1 in 2500 pregnancies. Of these, about 75% to 80% are placenta accreta, about 17% are placenta increta, and the remaining 5% or more is placenta percreta. The incidence of placenta percreta is very low, recently the occurrence of this occurrence is related to the quality of the cesarean itself.^{3-6,8-10} About 75% of cases of placenta percreta are associated with placenta previa. Most cases of placenta percreta involving the bladder are recognized only at delivery if there are no urinary symptoms.^{3,4,10,17} Surprisingly, gross hematuria is rare even when the bladder is infiltrated and occurs in only about 25% of these cases.^{5,11-13} Some patients with placenta percreta even describe a history of dull and persistent lower abdominal pain during their pregnancy. This is due to placental infiltration in the bladder tissue, in contrast to placenta previa in general without pain. Microscopic or gross



eISSN : 2579-8324

pISSN : 2579-8323

ANDALAS OBSTETRICS AND GYNECOLOGY JOURNAL

Address for Correspondence

Editorial Room Andalas Obstetrics and Gynecology Journal, 3rd floor of KSM of Obstetrics and Gynecology, RSUP DR. M. Djamil Padang, Jl. Perintis Kemerdekaan Padang, Sumatera Barat 25127

Website:

<http://jurnalobgin.fk.unand.ac.id/index.php/JOE>

hematuria should be further evaluated in order to raise suspicion in placenta percreta. ^{3,4,6,10-13}

Evaluation to identify placenta percreta requires ultrasound, magnetic resonance imaging (MRI), and cystoscopy. Sonographic findings during the second and third trimesters include placenta lacunae (vascular lakes of various shapes and sizes seen in the parenchyma of the placenta), irregular boundaries between the bladder and myometrium, thin myometrium, and loss of empty space from placenta (loss of the decidual layer). Doppler ultrasound often shows turbulent blood flow from the placenta to the surrounding tissues. Cystoscopy will show abnormalities in the bladder wall. As much as possible avoid bleeding due to biopsy. ^{4,6,10-14,15}

Operative handling of placenta percreta, should be avoided by manual removal of the placenta. After labor occurs, the unstoppable uterine bleeding from the retained portion of the placenta can force the obstetrician to perform a hysterectomy. Intraoperative internal iliac artery embolization after preoperative cannulation or prophylactic bilateral ligation may be performed to prevent excessive blood loss at hysterectomy. Conservative management with methotrexate in these patients is not feasible. ^{3,4,5,10-14,16}


In the presence of invasion of the bladder wall and in the setting of uncontrolled uterine bleeding after delivery, every effort should be made to preserve the bladder, as this has been shown to make sense as long as the integrity of the ureters is established during and after surgery. Reconstructive surgery, if necessary, can be postponed until the patient is hemodynamically stabilized. ^{7-11,14-17} Although removal of the posterior bladder and distal ureter has been recommended if invasion is found at that time it certainly affects quality of life later in life. ^{4,5,7,10-14,17-22}

CONCLUSION

Management is recommended in cases of placenta percreta, planning a premature cesarean hysterectomy with the placenta left in situ. However, the diagnosis is made based on the anatomical pathology results obtained after hysterectomy, and is not considered a first-line treatment for women who still wish to maintain future fertility.

REFERENCES

1. Fitzpatrick, Kathryn E et al. "Incidence and risk factors for placenta accreta/increta/percreta in the UK: a national case-control study." *PloS one* vol. 7,12 (2012): e52893.
2. Ibrahim MA, Liu A, Dalpiaz A, Schwamb R, Warren K, Khan SA. Urological manifestations of placenta percreta. *Curr Urol* 2015;8:57-65



eISSN : 2579-8324

pISSN : 2579-8323

ANDALAS OBSTETRICS AND GYNECOLOGY JOURNAL


Address for Correspondence

Editorial Room Andalas Obstetrics and Gynecology Journal, 3rd floor of KSM of Obstetrics and Gynecology, RSUP DR. M. Djamil Padang, Jl. Perintis Kemerdekaan Padang, Sumatera Barat 25127

Website:

<http://jurnalobgin.fk.unand.ac.id/index.php/JOE>

3. Konijeti, Ramdev et al. "Placenta percreta and the urologist." *Reviews in urology* vol. 11,3 (2009): 173-6.
4. Tillu, Neeraja et al. "Placenta percreta with bladder invasion: The armamentarium available in its management." *Urology annals* vol. 11,3 (2019): 324-327.
5. Sentilhes L, Goffinet F, Kayem G. Management of placenta accreta. *Acta Obstet Gynecol Scand Wiley*. 2013;92:1125–34
6. Banu H, Hui JW, Hui L, Hua L. Central placenta previa with placenta percreta partially invading bladder: a case report. *Int J Reprod Contracept Obstet Gynecol* 2015;4:859-62
7. Wagaskar VG, Daga SO, Patwardhan SK. Placenta percreta presenting with delayed haematuria. *J Clin Diagn Res*. 2015;9:PD01–2.
8. Koukoura O, Lialios G, Garas A, Sveronis G, Nidimos A, Gkorezi I, Alevra Z, Tzortzis V, Oeconomou A, Zachos I, Daponte A. Macroscopic Hematuria due to Placenta Percreta: Report of Two Cases and Short Review. *Case Rep Obstet Gynecol*. 2017;2017:9863792.
9. Gupta P, Pradeep Y, Goel A, Singh R. Hematuria: An Unusual Presentation of Placenta Percreta. *Urology*. 2012. 80(2): e13–e14.
10. Kayem G, Deneux-Tharaux C, Sentilhes L, PACCRETA group. PACCRETA: clinical situations at high risk of placenta ACCRETA/percreta: impact of diagnostic methods and management on maternal morbidity. *Acta Obstet Gynecol Scand*. 2013; 92: 476– 82.
11. Esakoff TF, Handler SJ, Granados JM, Caughey AB. PAMUS: placenta accreta management across the United States. *J Matern Fetal Neonatal Med*. 2012; 25: 761– 5.
12. Hayes E, Ayida G, Crocker A. The morbidly adherent placenta: diagnosis and management options. *Curr Opin Obstet Gynecol*. 2011; 23: 448– 53.13.
13. Sentilhes L, Descamps P, Goffinet F. Arteriovenous malformation following conservative treatment of placenta percreta with uterine artery embolization but no adjunctive therapy. *Am J Obstet Gynecol*. 2011; 205: e13.
14. Bouvier A, Sentilhes L, Thouveny F, Bouet PE, Gillard P, Willoteaux S, et al. Planned caesarean in the interventional radiology cath lab to enable immediate uterine artery embolization for the conservative treatment of placenta accreta. *Clin Radiol*. 2012; 67: 1089– 94.
15. Alanis M, Hurst BS, Marshburn PB, Matthews ML. Conservative management of placenta increta with selective arterial embolization preserves future fertility and results in a favorable outcome in subsequent pregnancies. *Fertil Steril*. 2006; 86: 1514. e3–7.
16. Wang Z, Li X, Pan J, Zhang X, Shi H, Yang N, Jin Z. Uterine Artery Embolization for Management of Primary Postpartum Hemorrhage Associated with Placenta Accreta. *Chin Med Sci J*. 2016 Nov 20;31(4):228-232.
17. Chen C, Lee SM, Kim JW, Shin JH. Recent Update of Embolization of Postpartum Hemorrhage. *Korean J Radiol*. 2018 Jul-Aug;19(4):585-596. doi: 10.3348/kjr.2018.19.4.585. Epub 2018 Jun 14.
18. Dhinakaran P, Krishnamoorthy S, Rajamanickam G M, Reddy K S, Pargal R. Placenta



eISSN : 2579-8324

pISSN : 2579-8323

ANDALAS OBSTETRICS AND GYNECOLOGY JOURNAL

Address for Correspondence

Editorial Room Andalas Obstetrics and Gynecology Journal, 3rd floor of KSM of Obstetrics and Gynecology, RSUP DR. M. Djamil Padang, Jl. Perintis Kemerdekaan Padang, Sumatera Barat 25127

Website:

<http://jurnalobgin.fk.unand.ac.id/index.php/JOE>

- Percreta with urinary bladder infiltration : a modified posterior approach a case report and lessons learnt. *International Journal of Scientific Study*. 2018. p:134-6.
19. Tillu N, Savalia A, Patwardhan Sujata, Bhushan P. Placenta percreta with bladder invasion : The armamentarium available in its management. *Urology Annals*. 2019. p: 324-7.
 20. Torrez-Morales F, Briones-Garduno J. Clinical case : Placenta percreta with bladder and rectum invasion. *Circen*. 2016.. p:1-4.
 21. Abbas A, Ali S E, Michael A, Ali S. Successful fertility-preserving management of a case of placenta percreta invading the urinary bladder and anterior abdominal wall: A case report. *Middle East Fertility Society Journal*. 2018. p: 77-80.
 22. Lialios G, Garas A, Sveronis G, Nidimos A, Gkorezi I, Alevra ZV, et al. Macroscopic hematuria due to placenta percreta : Report of two cases and short review. *Hindawi Case Reports in Obstetrics and Gynecology*. 2017.