



## CASE REPORT

### Adult Women with Congenital Adrenal Hyperplasia (CAH)

Muhammad Rudi Setiawan<sup>1</sup>, Ichsan Arif<sup>2</sup>, Bobby Indra Utama<sup>3</sup>

**Affiliations:** 1. Obstetrics and Gynecology Department, Dr. M. Djamil Central General Hospital Padang, West Sumatera, Indonesia, 2. Obstetrics and Gynecology Department, Dr. M. Djamil Central General Hospital Padang, West Sumatera, Indonesia; 3. Sub Division of Urogynecology, Obstetrics and Gynecology Department, Faculty of Medicine, Andalas University, Dr. M. Djamil Central General Hospital Padang, West Sumatera, Indonesia

**Correspondence:** Ichsan Arif, email : [drihsanarif@gmail.com](mailto:drihsanarif@gmail.com), Hp +6285271501003

#### Abstract

**Introduction :** Congenital Adrenal Hyperplasia (CAH) is the most common cause of ambiguous genitalia. It is a genetic disorder that occurs due to failure or disruption of the formation of enzymes which play a role in the production of cortisol and aldosterone and can cause fusion of the labia, clitoromegaly, and a fusion of the vagina and distal urethra.

**Case Reports:** A 32-year-old patient, unmarried, came to the urogynecology department complaining of thickening of the upper genitalia that resembles male genitalia. This problem has been known to the patient since she was 16 years old and was brought to the doctor at the age of 21 and diagnosed with congenital adrenal hyperplasia. The patient has had menstruation since she was 14 years old, but it is irregular. Since 8 years ago, the patient has been regularly taking hydrocortisone from an internal medicine specialist but has never been to the obstetrics and gynecology department for 8 years, now the patient comes to the urogynecology department because she wants to get married. When the patient was in school, she grew up like a normal woman and have good academic abilities. In the family history, there was no family history of congenital abnormalities. From physical examination, her height is 150 cm. She shows the habitus of external body like a woman. On genital examination found no formation of labia, clitoromegaly. Karyotype 46, XX. Ultrasonography found uterus and ovaries within normal limits.

**Conclusion:** Counseling, both surgical and non-surgical treatment with a multidisciplinary approach, will give good results in patients with CAH. Rapid diagnosis and treatment will provide good management for patients with CAH. Surgery in the form of reducing the size of the clitoris (while maintaining the function of sensation), as well as expanding the vaginal opening can help in these patients to improve the patient's quality of life.

**Keywords:** Congenital Adrenal Hyperplasia; clitoromegaly; unmarried

## INTRODUCTION

Congenital adrenal hyperplasia (CAH) is the most common cause of ambiguous genitalia and is estimated to occur in 1 in 14,000 births in the UK. The pathogenesis in most cases is 21-hydroxylase deficiency.<sup>1</sup> Deficiency of this enzyme results in a decrease in cortisol levels, which in turn leads to increased secretion of adrenocorticotropic hormone (ACTH). This causes an increase in cortisol precursor levels that is forced along the androgen pathway. In more severe forms, aldosterone levels will also be low, which can result in salt-wasting, volume depletion, hypotension, decreased renal blood flow, and increased renin activity. The goal of treatment in this patient is to replace aldosterone with fludrocortisone and replace glucocorticoids to suppress excess ACTH activity. Manifestations differ depending on the form of the disease and

Correspondence: Ichsan Arif, email : [drichsanarif@gmail.com](mailto:drichsanarif@gmail.com)



eISSN : 2579-8324

**Address for Correspondence:**Editorial Room Andalas Obstetrics and Gynecology Journal, 3<sup>rd</sup> floor of KSM of Obstetrics and Gynecology, RSUP DR. M. Djamil Padang, Jl. Perintis Kemerdekaan Padang, Sumatera Barat 25127**Website:**pISSN : 2579-8323 <http://jurnalobgin.fk.unand.ac.id/index.php/JOE>

can include crises of salt excretion in the neonate and ambiguous genitalia until puberty prematurely or virilization at puberty. However, the majority of cases are diagnosed in neonates who are found to have genitalia ambiguous or masculinized at birth. Virilization of the female genitalia occurs to varying degrees, causing fusion of the labia, clitoromegaly, and a fusion of the vagina and distal urethra. Although the fertility rate in these women is lower than normal, it does not affect the pregnancy rate.

The surgical procedure involves corrective surgery of the genitalia to separate the labia, reduce the size of the clitoris, and separate the vagina and urethra. The goal is to establish a feminine appearance, allow menstrual flow, maintain sexual function, and prevent urinary tract complications in the future. This is usually done as a one-step procedure at a time baby, although many patients require follow-up surgery at teenager to allow menstrual flow and allow penetration of sexual intercourse. There has been increasing controversy recently among clinicians and patient support groups regarding the need and timing of surgery for genital feminization. Genital surgery is associated with injury to the sensory innervation of the clitoris and is associated with loss of sexual sensation and an increased risk of sexual dysfunction. However, long-term data are scant and no consensus has been reached at this time.<sup>1</sup>

**CASE REPORT**

A 32-year-old patient, unmarried, came to the urogynecology department complaining of thickening of the upper genitalia resembling male genitalia. This problem has been known to the patient since he was 16 years old and was brought to the doctor at the age of 21 and diagnosed with congenital adrenal hyperplasia. The patient claimed to have had menstruation since he was 14 years old, but not every month and a little. Since 8 years ago, the patient routinely took hydrocortisone from an internal medicine specialist but had never been to the obstetrics and gynecology department for 8 years, now the patient comes to the urogynecology department because he wants to get married. which is quite good. In the family history, there was no family history of congenital abnormalities. From a physical examination, his height is 150 cm. He shows the habitus of the external body like a woman. From genital examination, pubic hair appears, enlargement of the clitoris is similar to that of a male penis.

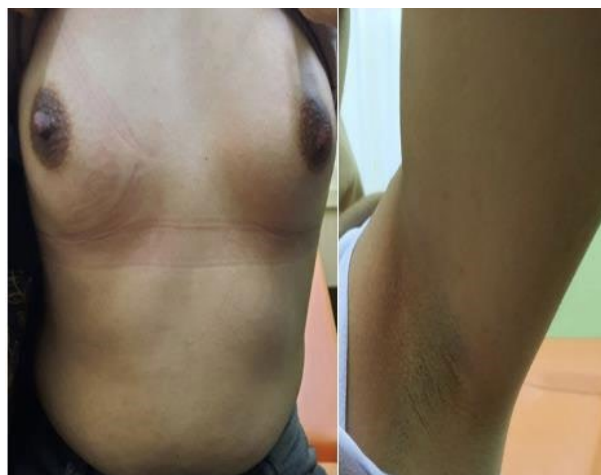

Figure 1. Secondary sexual characteristics: (A) Breast, (B) Axilla

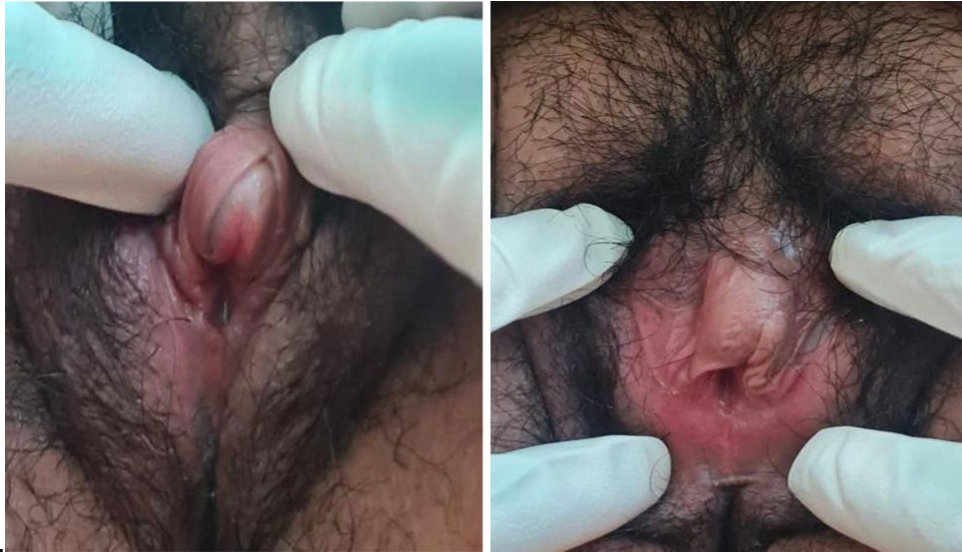


Figure 2. Adults with congenital adrenal hyperplasia

The results of a complete hematological examination did not show any abnormalities. Hormone examination found LH, FSH, Estradiol, Testosterone, DHEA-S, Kortisol was within normal limits, and cytogenetic analysis revealed 46, XX, apparently a normal female karyotype.

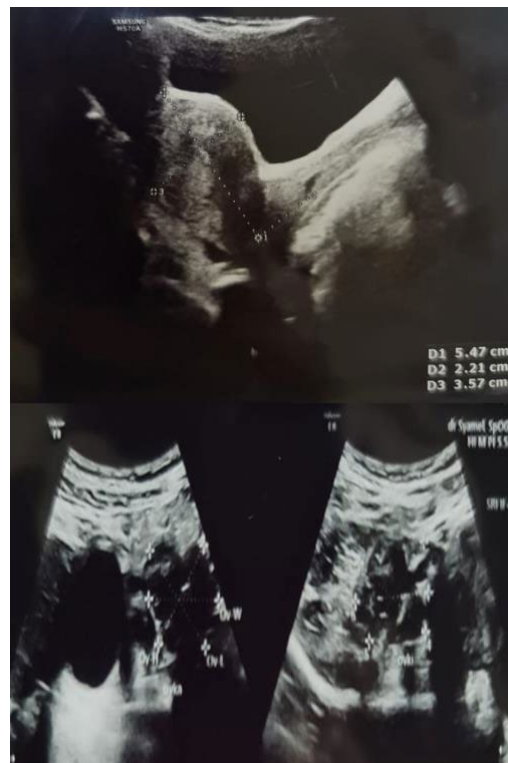

Figure 3. Ultrasound of the uterus and ovaries

Ultrasound showed normal uterus and ovaries. The CT scan of the abdomen showed no abnormalities in the kidneys or pelvic organs



eISSN : 2579-8324

pISSN : 2579-8323

## DISCUSSION

Congenital adrenal hyperplasia (CAH) is an autosomal recessive disorder, resulting in deficient adrenal cortisol production with excess adrenal androgen production. These various conditions hit 1 in 14,000–15,000 newborns.<sup>1,7</sup> The most common form results in deficiency of the 21-hydroxylase enzyme, diverting steroid precursors from cortisol (glucocorticoid) and aldosterone (mineralocorticoid) production and increasing adrenal androgen biosynthesis.<sup>8</sup> There are two clinical subtypes of CAH: nonclassical and classic. In classic CAH, 46 XX female fetuses are virilized in utero due to their increased exposure to androgens. This results in the development of clitoromegaly, fusion of the labioscrotal folds, and formation of the common urogenital sinus, classified as simple virilising, or salt-wasting, in which there is also a deficiency of adrenal aldosterone production.<sup>3,10</sup> Adequate replacement of glucocorticoids in affected individuals results in near-normal adrenal androgen production.<sup>4,9</sup>

This patient was diagnosed with CAH at the age of 21 years by the Department of Internal Medicine and Endocrine Gynecology.<sup>5,11</sup> For eight years, the patient was a regular follow-up to the Department of Internal Medicine, but not to the Department of Endocrine Gynecology.<sup>2,12</sup> Because the patient intended to get married, the patient came to the Urogynecology Department with complaints of thickening resembling male genitalia in the upper genitalia and worries about sexual problems.<sup>3,14</sup> Because the patient was routinely controlled since 2014 until now, not much change occurred in the size of the thickened clitoris, and there were no complaints. This is likely because the patient has been taking hydrocortisone regularly.<sup>15</sup>

In adults and adolescents after epiphyseal closure, treatment with long-acting steroids is recommended.<sup>16</sup> Treatment was monitored with periodic measurements of 17-hydroxyprogesterone, androstenedione, and testosterone levels every 3–4 months during the pubertal phase and 6 months to annually when the glucocorticoid dose is well established.<sup>17</sup> The goal is to maintain levels of these hormones that are only slightly elevated. The dose of glucocorticoids should be increased during stressful events, labor and delivery.<sup>3</sup> Hydrocortisone is the drug of choice, but prednisolone or dexamethasone may also be used. The dose of hydrocortisone is 12–18 mg/m<sup>2</sup>/day, while the dose of prednisolone is 5–7.5 mg/day.<sup>4</sup>

In a biological context, the elevated androgen levels found in patients with CAH are known to cause several problems after puberty, including menstrual disturbances, hirsutism, and inadequate vaginal introitus. Moreover, patients may present with genital abnormalities such as ambiguity or clitoromegaly, and requires surgical treatment.<sup>5</sup>

Women who underwent surgery reported a sexual function score of 25.13 using the Female Sexual Function Index (maximum score, 36).<sup>18</sup> Many patients continue to complain of a marked decrease in clitoral sensitivity, difficulty vaginal penetration, and a low frequency of sexual intercourse. Most of the patients were sexually active, but only 48% reported comfortable sexual intercourse.<sup>19</sup> Most patients (79.4%) and treating health care professionals (71.8%) were satisfied with the surgical outcome. Vaginal stenosis is common (27%), and other



surgical complications, such as fistulas, urinary incontinence, and urinary tract infections, are less common, according to Almasri et al.<sup>6</sup>

In this patient, genital reconstruction was performed in the form of clitoral reduction (clitoreduction).<sup>20</sup>

## CONCLUSION

Counseling, management both surgical and non-surgical with a multidisciplinary approach, will give good results in patients with CAH. Rapid diagnosis and treatment will provide good management for patients with CAH but in these patients there are already delays in surgical management.

## REFERENCES

1. Davies MC, Creighton SM. Gynecological Developmental Abnormalities. In: Cardozo L, editor. Textbook of Female Urology and Urogynecology. 1. 4th ed. Boca Raton: CRC Press; 2017. p. 1684-5.
2. Heland S, Hewitt JK, McGillivray G, Walker SP. Preventing female virilization in congenital adrenal hyperplasia: The controversial role of antenatal dexamethasone. *Aust NZJ Obstet Gynaecol.* 2016;56(3):225-32.
3. Shenoy S, Gopishyam M. Successful Treatment Outcome in a Woman with Congenital Adrenal Hyperplasia. *J Obstet Gynaecol India.* 2019;69(2):188-91.
4. Akhtar N, Hayat Z, Bari A. Female Pseudo Hermaphroditism: Late Onset Congenital Adrenal Hyperplasia. *J Ayub Med Coll Abbottabad.* 2018;30(3):458-62.
5. Gondim R, Teles F, Barroso U, Jr. Sexual orientation of 46, XX patients with congenital adrenal hyperplasia: a descriptive review. *J Pediatr Urol.* 2018;14(6):486-93.
6. Almasri J, Zaiem F, Rodriguez-Gutierrez R, Tamhane SU, Iqbal AM, Prokop LJ, et al. Genital Reconstructive Surgery in Females With Congenital Adrenal Hyperplasia: A Systematic Review and Meta-Analysis. *J Clin Endocrinol Metab.* 2018;103(11):4089-96.
7. Jayakrishnan R, Lao Q, Adams SD, Ward WW, Merke DP. Revisiting the association of HLA alleles and haplotypes with CYP21A2 mutations in a large cohort of patients with congenital adrenal hyperplasia. *Gene.* 2019 Mar 01;687:30-34.
8. Gondim R, Teles F, Barroso U. Sexual orientation of 46, XX patients with congenital adrenal hyperplasia: a descriptive review. *J Pediatr Urol.* 2018 Dec;14(6):486-493.
9. Al-Mendalawi MD. Comment on: Growth characteristics in children with congenital adrenal hyperplasia. *Saudi Med J.* 2018 Nov;39(11):1164.
10. Barbaro M, Soardi FC, Ostberg LJ, et al. In vitro functional studies of rare CYP21A2 mutations and establishment of an activity gradient for nonclassic mutations improve phenotype predictions in congenital adrenal hyperplasia. *Clin Endocrinol (Oxf)* 2015;82:37.
11. Speiser PW, Arlt W, Auchus RJ, Baskin LS, Conway GS, Merke DP, Meyer-Bahlburg HFL, Miller WL, Murad MH, Oberfield SE, White PC. Congenital Adrenal Hyperplasia Due to Steroid 21-Hydroxylase



**Address for Correspondence:**

Editorial Room Andalas Obstetrics and Gynecology Journal, 3<sup>rd</sup> floor of KSM of Obstetrics and Gynecology, RSUP DR. M. Djamil Padang, Jl. Perintis Kemerdekaan Padang, Sumatera Barat 25127

**Website:**

pISSN : 2579-8323 <http://jurnalobgin.fk.unand.ac.id/index.php/JOE>

eISSN : 2579-8324

Deficiency: An Endocrine Society Clinical Practice Guideline. *J Clin Endocrinol Metab.* 2018 Nov 01;103(11):4043-4088.

12. Bruque CD, Delea M, Fernandez CS, et al. Structure-based activity prediction of CYP21A2 stability variants: A survey of available gene variations. *Sci Rep.* 2016 Dec 14;6:39082.
13. Rushworth RL, Torpy DJ, Stratakis CA, Falhammar H. Adrenal Crises in Children: Perspectives and Research Directions. *Horm Res Paediatr.* 2018;89(5):341-351.
14. El-Maouche D, Hargreaves CJ, Sinaii N, Mallappa A, Veeraraghavan P, Merke DP. Longitudinal Assessment of Illnesses, Stress Dosing, and Illness Sequelae in Patients With Congenital Adrenal Hyperplasia. *J Clin Endocrinol Metab.* 2018 Jun 01;103(6):2336-2345.
15. Witchel, Selma Feldman. Congenital Adrenal Hyperplasia. *Journal of pediatric and adolescent gynecology* vol. 30,5 (2017): 520-534.
16. Mallappa A, Nella AA, Sinaii N, Rao H, Gounden V, Perritt AF, Kumar P, Ling A, Liu CY, Soldin SJ, Merke DP. Long-term use of continuous subcutaneous hydrocortisone infusion therapy in patients with congenital adrenal hyperplasia. *Clin Endocrinol (Oxf).* 2018 Oct;89(4):399-407.
17. Tamhane S, Rodriguez-Gutierrez R, Iqbal AM, Prokop LJ, Bancos I, Speiser PW, Murad MH. Cardiovascular and Metabolic Outcomes in Congenital Adrenal Hyperplasia: A Systematic Review and Meta-Analysis. *J Clin Endocrinol Metab.* 2018 Nov 01;103(11):4097-4103
18. Herbison AE. Control of puberty onset and fertility by gonadotropin-releasing hormone neurons. *Nat Rev Endocrinol.* 2016;12:452.
19. Walia R, Singla M, Vaiphei K, Kumar S, Bhansali A. Disorders of sex development: a study of 194 cases. *Endocr Connect.* 2018 Feb;7(2):364-371.
20. Milyani AA, Al-Agha AE, Al-Zanbagi M. Initial presentations and associated clinical findings in patients with classical congenital adrenal hyperplasia. *J Pediatr Endocrinol Metab.* 2018 Jun 27;31(6):671-673.