



eISSN : 2579-8324 pISSN : 2579-8323

## CASE REPORT

### Ovarian goiter with papillary thyroid carcinoma: A very rare case

Puja Agung Antonius<sup>1</sup>, Syamel Muhammad<sup>1</sup>, Muhammad Zaldy Rasyid Putra<sup>2</sup>, Santy Saberko<sup>3</sup>

1. Sub-Division of Gynecological Oncology, Obstetrics and Gynecology Division, RSUP DR M DJAMIL Padang/Faculty of Medicine, Andalas University; 2. PPDS Obstetrics and Gynecology Faculty of Medicine, Andalas University; 3. Anatomical Pathology Section at M Natsir Hospital Solok

---

---

#### Abstract

*Struma ovarii is a rare condition, in which thyroid tissue is the predominant element in an ovarian carcinoma. Thyroid tissue may demonstrate the same spectrum of pathological features as in the normal thyroid including benign and malignant changes. The malignant type is very rare, only 5% from all incidents of goiter ovarii. We present a case of papillary thyroid carcinoma arising in a struma ovarii of the right ovary in a 43-year-old female*

**Keywords:** papillary thyroid carcinoma; goiter ovary; ovarian tumor

#### BACKGROUND

Ovarian goiter (SO) is defined as an ovarian tumor that is predominantly (more than 50%) or entirely composed of thyroid tissue.<sup>1</sup> It may exhibit pathological features that can be seen in a normal thyroid including both benign and malignant changes.<sup>2</sup> Ovarian goiter itself is a rare condition and account for only about 1% of ovarian tumors and 2.7% of dermoid cysts.<sup>1</sup> Most SO are benign tumors (95%) and the remainder are malignant.<sup>2</sup> Malignant type is the rarer type, only 5% of goitre ovaries. It can be concluded that the incidence of papillary thyroid carcinoma is only about 0.0005% of all ovarian tumors. We present a case of papillary thyroid carcinoma arising in the right ovarian goiter in a 43-year-old woman.

#### CASE DESCRIPTION

Our patient is a 43 year old woman, gravida 3 para 3 coming to the polyclinic of RSUD Dr. M. Natsir with complaints of bloated stomach since 6 months ago and pain in the stomach since 1 month ago; At the time of initial discovery, the right adnexal mass measured 7.1 x 7.4 x 5.1 cm and contained both cystic and solid components. There is no significant internal blood flow. The patient was diagnosed with a right ovarian tumor and followed up with an abdominal ultrasound examination.

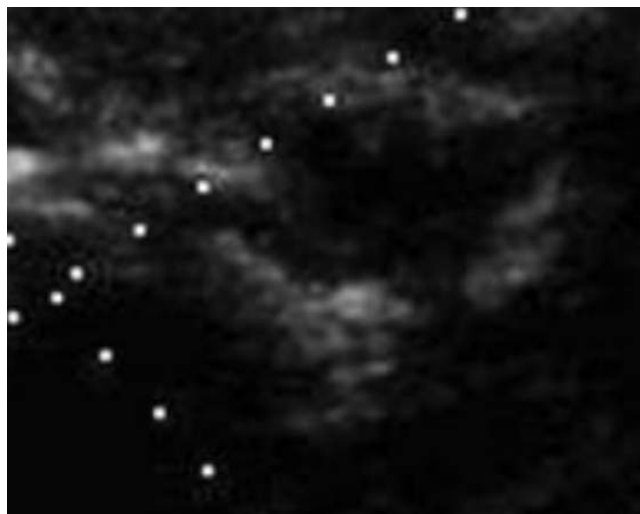


Figure 1: Transabdominal grayscale ultrasound image showing a heterogeneous lesion showing a solid and cystic portion arising from the right ovary.

The patient had no clinical signs of hyperthyroidism. The patient underwent a complete blood count and thyroid function tests. All examinations were within normal limits.

The patient opted for laparotomy and right salpingo-oophorectomy, and was performed with the removal of a 9.5 x 5.5 x 3.5 cm multilobular cystic mass along with the attached right fallopian tube segment. The histopathological report was of papillary thyroid carcinoma presenting on SO [Figure 2], without capsular invasion.

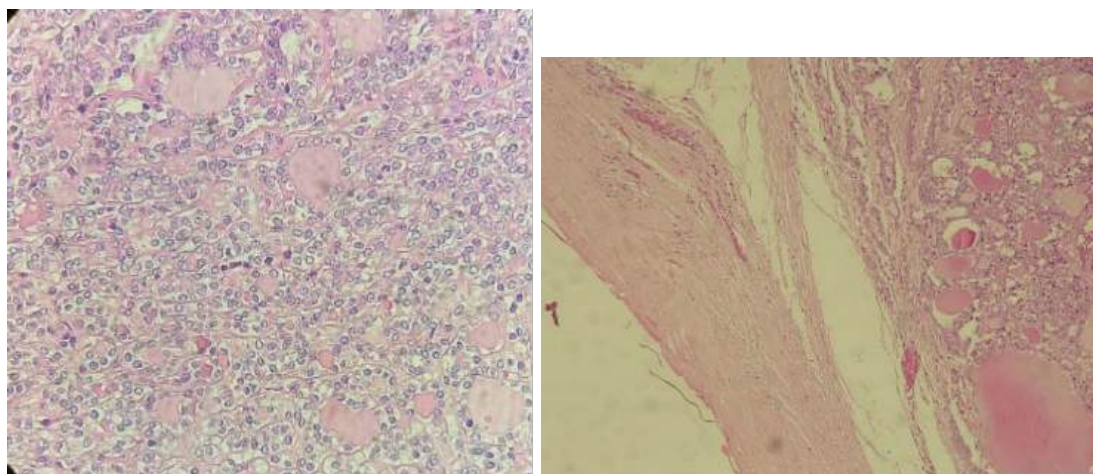


Figure 2: Hematoxylin and eosin-stained tissue (40x and 20x) showing papillae with cells with bright, large nuclei and thick nuclear membranes (groundglass aperture), consistent with papillary thyroid carcinoma arising in the goiter ovarii.

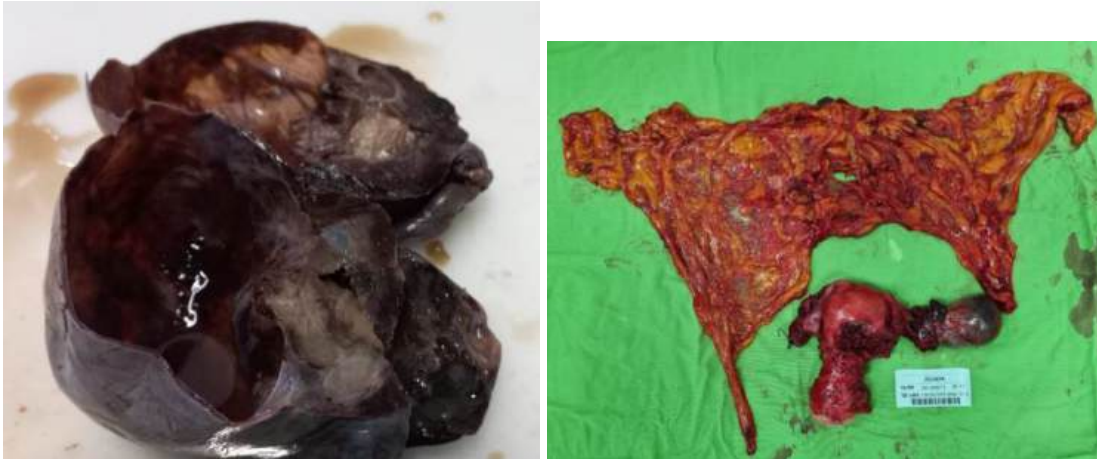

Figure 3. Ovarian tumor solid and cystic mass with uterine tissue, contralateral adnexa and omentum.

The patient was then referred to Dr. M. Djamil Padang after knowing the results of the anatomical pathology is a papillary thyroid carcinoma. The patient was then advised to undergo surgical staging and the patient agreed. After surgical staging, the tissue was examined and the anatomical pathology results showed no malignant tissue found in the uterus, contralateral ovary, omentum and peritoneal washing cytology, it was concluded that the diagnosis in this patient was Struma Ovarii with Papillary Thyroid Carcinoma stage IA1. The patient was planned for follow-up, for thyroid ultrasound examination and follow-up of thyroid function to ensure that there is no hyperthyroidism and no malignancy in the thyroid organ. Patients were advised to undergo chemotherapy with a regimen of Foncopac 280 mg and Carboplatin 480 mg for 6 cycles.

## DISCUSSION

Ovarian goiter was first described by Ludwig Pick that this tumor is composed of thyroid tissue and suggested that ovarian goiter is actually a teratoma in which thyroid elements have grown on top of other tissue.<sup>3</sup> The age incidence of ovarian goitre is 20-40 years, similar to that of adult cystic teratoma.<sup>1</sup> The peak age incidence of goiter ovary is in the fifth decade, but cases have been reported in perimenopausal women and are rare in prepubertal girls.<sup>1</sup>

Patients usually present with signs and symptoms of a pelvic mass, ascites in one third of cases, and occasionally the patient has Meigs syndrome.<sup>1</sup> Less than 5% of goiter ovaries are associated with hyperthyroidism. Because 95% of goitre ovarii are benign and usually occur in premenopausal women, preoperative diagnosis is important to avoid unnecessary surgeries such as hysterectomy and pelvic lymph node dissection.<sup>4</sup>

Sonographically, goiter ovarii appears similar to a mature cystic teratoma, with a mean tumor diameter of 5.7 cm (3–9.5 cm). Zalel et al described the typical finding in a series of 251 cystic



eISSN : 2579-8324 pISSN : 2579-8323

teratomas in which they demonstrated the presence of abundant blood flow in the center of the goiter ovarian tumor and the reason for this finding could be attributed to the presence of highly vascularized thyroid tissue compared to the avascular fat and hair found in common teratomas.<sup>5</sup> Although the imaging findings of goiter ovary are nonspecific, ultrasound shows a complex appearance with multiple cystic and solid areas and multilobular surfaces, reflecting the pathological features of the tumor.<sup>6</sup>

In most cases, the thyroid tissue within the tumor does not produce large amounts of thyroid hormone. However, in a minority of cases, the tumor behaves autonomously and produces excessive thyroid hormone. This in turn suppresses the normal thyroid and causes thyrotoxicosis. Scintigraphy performed with Iodine-131 is useful for diagnosing goiter ovarian hyperfunction based on the higher radionuclide uptake by the ovarian mass than by the thyroid gland in the neck.<sup>7</sup>

When goiter ovary is not associated with hyperthyroidism, the differential diagnosis should include mature cystic teratoma without fat tissue, cystadenoma or cystadenocarcinoma, endometriosis, tuboovarian abscess, and metastatic tumors because the imaging features of these tumors may be similar to those of ovarian goitre.<sup>8</sup>

Ovarian goiter histopathology usually consists of normal thyroid tissue consisting of thyroid follicles of various sizes and is often associated with a mature cystic teratoma.<sup>1</sup> Occasionally, thyroid tissue may show changes associated with hyperactivity, hypoactivity, or appear as an adenomatous nodule or nodular goiter. . Uniformly accepted criteria for malignancy in goiter ovary have not been established. Due to different uses and lack of precise definitions, it is recommended that the term "malignant goiter" be no longer used for cases of malignancy that develop in ovarian goitre. The term "thyroid-type carcinoma originating in the goiter ovary" (determining its type) is more appropriate to describe this entity.<sup>1</sup>

Papillary carcinoma is the most common thyroid type carcinoma in SO; Follicular carcinoma is the second most common type of carcinoma and varies in degree of differentiation.<sup>1</sup> It is important to note that the histologic changes of malignancy in SO, however, are often not the same as clinically malignant behavior, and the majority of cases of thyroid-type carcinoma arising in the goiter ovary do not have an aggressive clinical course.<sup>1</sup>

Because of their rarity, there is no agreement in the diagnosis and management of these tumors.<sup>9</sup> Although these tumors are relatively inert, most authors recommend surgery and debulking of the metastases followed by radioactive iodine. Total thyroidectomy is recommended to allow for effective ablative therapy with Iodine-131, to facilitate follow-up and to exclude, by careful histologic examination, primary thyroid cancer.<sup>10</sup>

Follow-up examinations in patients with thyroid-type carcinoma include assessment of thyroglobulin levels and Iodine-131 scan, the same procedure used in cases of thyroid



eISSN : 2579-8324 pISSN : 2579-8323

carcinoma.<sup>9</sup> The rate of metastases is about 5-6% and can occur even 26 years after the primary disease.

## CONCLUSION

In summary, this case demonstrates imaging findings and correlations with histopathology of papillary thyroid carcinoma originating in the goiter ovary. Ovarian goiter is a rare entity that may be suggested when there is a finding of a complex, highly vascularized ovarian mass or a solid section visible on cross-sectional imaging. As evidenced in this case report, it is important to remember that a small proportion of goiter ovary is associated with thyroid-type carcinoma and this can significantly change patient management.

## REFERENCES

1. OSWALDO, Rodríguez-Juárez Irving, et al. Strumma ovarii: a case report and literature review. *International Surgery Journal*, 2022, 9.4:882-885.
2. LI, Sijian, et al. Clinical characteristics and survival outcomes of malignant goiter ovarii confined to the ovary. *BMC cancer*, 2021, 21.1:1-10.
3. YOUNG, Robert H. Ovarian tumors: A survey of selected advances of note during the life of this journal. *Human Pathology*, 2020, 95:169-206.
4. Pilarska Z, Grabska K, Fudalej M, Deptała A, Badowska-Kozakiewicz A. What is new about germ cell ovarian tumors?. *Oncol in Clinical Practice*. 2022; 18(2): 115-118.
5. Saleh M, Bhosale P, Menias CO, Ramalingam P, Jensen C, Iyer R, & Ganeshan D. Ovarian teratomas: clinical features, imaging findings and management. *Abdominal Radiology*, 2021 46(6), 2293–2307.
6. Srisajjakul S, Prapaisilp P, & Bangchokdee S. Imaging features of unusual lesions and complications associated with ovarian mature cystic teratoma. *Clinical Imaging* 2019. 57, 115–123.
7. Singh M, Bhandary RR, Pariyar J, Masky S, Dhakal HP. Struma ovarii: A rare entity. *J Pathol Nep* 2021;11:1898-1901.
8. Mukuda N, Ishibashi M, Murakami A, Fukunaga T, & Fujii S. Ovarian solid tumors: MR imaging features with radiological–pathologic correlation. *Japanese Journal of Radiology* 2020. 1-12.
9. Tzelepis, EG, Barendolts, E., Garzon, S., Shulan, J., & Eisenberg, Y. Unusual Case of Malignant Struma Ovarii and Cervical Thyroid Cancer Preceded by Ovarian Teratoma: Case Report and Review of the Literature. *Case Reports in Endocrinology*, 2019, 1–7.
10. Wu, M., Hu, F., Huang, X., Tan, Z., Lei, C., & Duan, D. Extensive peritoneal implant metastases of malignant struma ovarii treated by thyroidectomy and 131I therapy. *Medicine*, 2018. 97(51), e13867.