

eISSN : 2579-8324

pISSN : 2579-8323

Alamat Korespondensi:

Ruang Redaksi Andalas Obstetrics and Gynecology Journal, Lantai 3 PPDS Obstetri dan Ginekologi Universitas Andalas, RSUP DR. M. Djamil Padang, Jl. Perintis Kemerdekaan Padang, Sumatera Barat 25127

Website:

<http://jurnalobgin.fk.unand.ac.id/index.php/JOE>

CASE REPORT**Bicornu Uterus**

Herti Marni¹, Ferdinal Ferry², Bobby Indra Utama³

Affiliations : 1. Resident of Obstetrics and Gynecology, Faculty of Medicine, Andalas University, Dr. M. Djamil Central General Hospital Padang; 2. Sub Division of Social Obstetrics and Gynecology, Obstetrics and Gynecology Department, Faculty of Medicine, Andalas University, Dr. M. Djamil Central General Hospital Padang; 3. Sub Division of Urogynecology, Obstetrics and Gynecology Department, Faculty of Medicine, Andalas University, Dr. M. Djamil Central General Hospital Padang

Correspondence: Herti Marni, email : hertimarni01@gmail.com, Hp: 081364469077

Abstract

Background : Uterus bicornis subseptum is a deformity of the uterus such as the shape of the heart, the fundus appears to be curved inward, and has a barrier or wall inside to the uterine cavity. This abnormality occurs due to failure of the fusion of the left and right mullerian ducts. If pregnant, women who have this form of the uterus will usually experience a location abnormality, in which the fetus is often transverse or breech. However, women who have this disorder sometimes find it difficult to get pregnant so they experience infertility. In addition, there is usually a disturbance in the formation of the kidneys, but in this patient there was no abnormality in the urinary tract. In cases where the patient does not have children and a bicornu uterine abnormality is found, uterine repair is performed and it is hoped that with the uterine anatomy returning to normal, the patient can become pregnant.

Objective : Discuss the management of cases of congenital abnormalities of the internal genital organs in patients with a bicornu uterus.

Method : Case Report.

Case : Reported a patient aged 25 years with primary infertility 4 years and a bicornu uterus. In patients, chromotubation was performed first, after chromotubation, the patient was performed metroplasty to remove the bulkhead in the uterus and to repair the uterus. During the post-op follow-up at the hospital the patient did not show any signs of infection or acute abdomen, then the patient was discharged on day 5. The patient was advised to go to the OBGYN polyclinic regularly for further follow-up to the success of his uterine repair. Assessment can be done in several ways including transvaginal ultrasound to assess whether there is adhesions to the endometrium from the results of uterine repair, HSG, SIS or hysteroscopy can also be done in assessing the success of metroplasty in this patient.

Conclusion : After metroplasty in a patient with a bicornu uterus, further follow-up is required to determine the success of this procedure by performing a follow-up ultrasound.

Keywords: Bicornu uterus, metroplasty

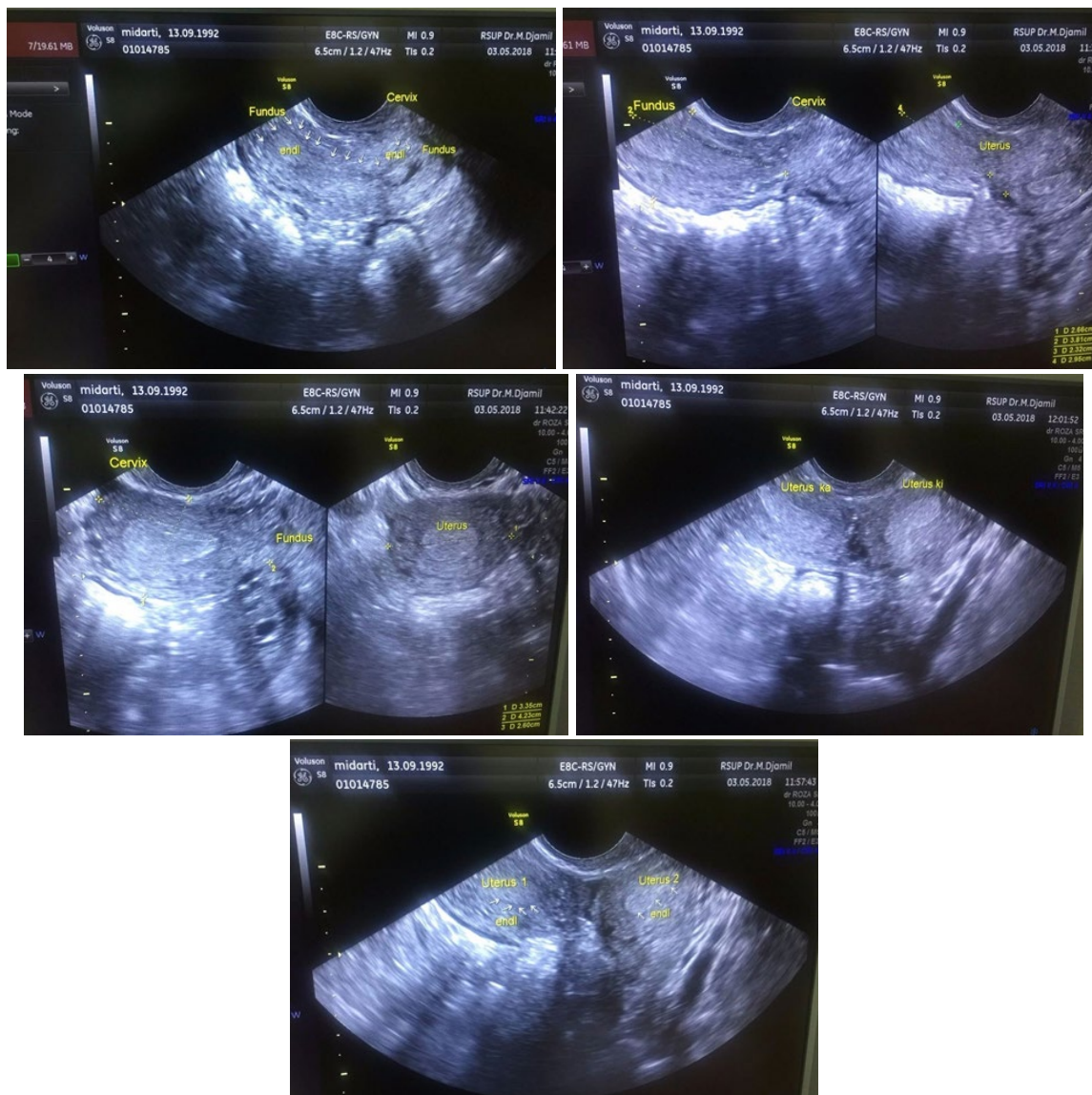
INTRODUCTION

The bicornis uterus is a malformation uterus resulted by Case A 25 year old patient came to the control of the imperfect muller duct fusion, is thought to occur the result mutation genes that express the factors that play a role in development duct muller. Generally asymptomatic, often found during pelvic examination, cesarean section, tubal sterilization, or evaluation of

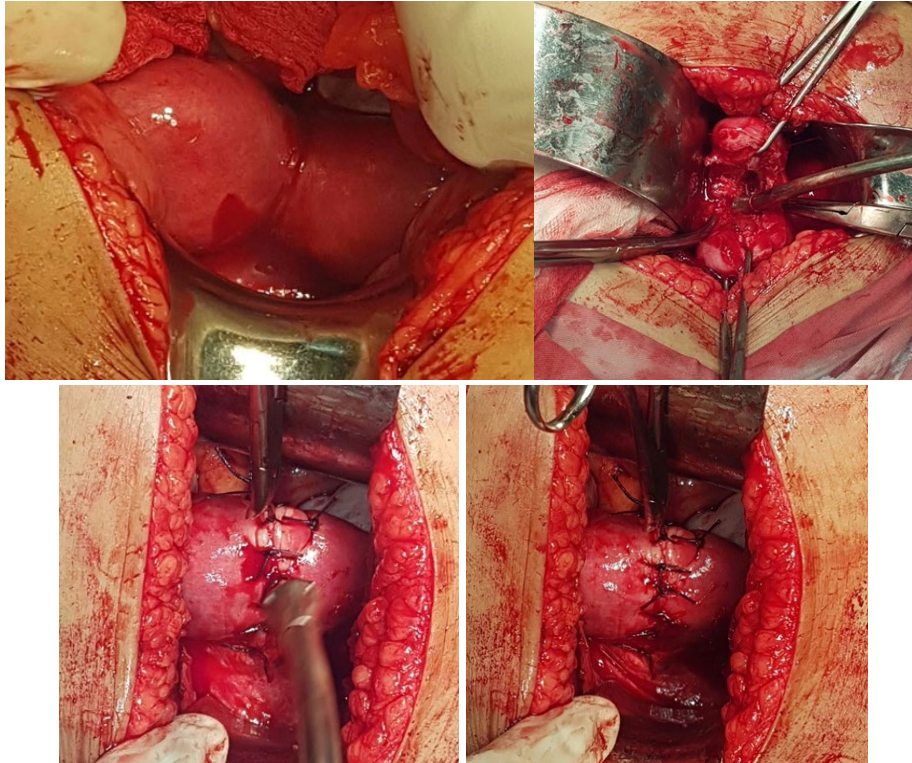
infertility. The management of the bikornis uterus includes surgical procedures as long as indicated and make it possible.

CASE REPORT

A 25 year old patient came to the control of the midwifery polyclinic of RSUP M Djamil Padang, the patient was referred from one of the district hospitals in West Sumatra (Dharmasraya) with 4 years of primary infertility and susp. Uterus bidelfis. The patient was evaluated and a diagnosis of Uterus was obtained bicornu. Next patient it is planned to do surgery metroplasty after done chromotubation. From the ultrasound examination, the bicornu uterus was visible, with 2 cavities, 1 cervix, endline (+), Size 3.35 x 4.23 x 2.60 cm and 6.4 x 2.3 x 2.93 cm. Both ovaries were within normal limits, suggesting a large uterus.



The patient was diagnosed with Susp. Uterus bicornu + Primary Infertility 4 years. Patient then managed with chromotubation + metroplasty.



DISCUSSION

Bicornu uterus is a case that is quite rare and asymptomatic, it is often known on other obstetric examinations or because it is evaluating infertility, in this patient was found during infertility examinations when he was in control at a hospital. After a definite diagnosis has been established, what is considered is the action to be taken, such as a metroplasty performed on this patient. There is a high probability of adhesion, so that urgent for performed the right action as well as complete control after the action.

REFERENCES

1. Borgohain D, Srivastava S. 2017. Pregnancy in bicornuate uterus. *International Journal of Reproduction, Contraception, Obstetrics and Gynecology*. Vol 7 (1): 346-346.
2. Ravikanth R. 2017. Bicornuate Uterus with Pregnancy. *Journal of Basic and Clinical Reproductive Science*. Vol 6 (2): Involved in the Development of the Female Reproductive Tract: A Possible Role for Gene Therapy. *J Genet Syndr Gene Ther*. Vol 4: 1-22. 149-150.



eISSN : 2579-8324

pISSN : 2579-8323

Alamat Korespondensi:

Ruang Redaksi Andalas Obstetrics and Gynecology Journal, Lantai 3 PPDS Obstetri dan Ginekologi Universitas Andalas, RSUP DR. M. Djamil Padang, Jl. Perintis Kemerdekaan Padang, Sumatera Barat 25127

Website:

<http://jurnalobgin.fk.unand.ac.id/index.php/JOE>

3. Madhavi D. 2012. Bicornuate Uterus - A Case Report. *Anat Physiol Journal*. Vol 2 (4): 1-2.
4. Chandler TM, Machan LS, Cooperberg PL, Harris AC, & Chang SD. 2009. Mullerian duct anomalies; from diagnosis to intervention. *The British Journal of Radiology*. Vol 82: 1034-1042.
5. Mezane S, Achenani M, Benabdejalil Y, Ziyadi M, Hafidi R, Hakimi I, et al. 2014. Bicornuate uterus and pregnancy a propos one case and review of the literature. *Journal of Gynecology and Obstetrics*. Vol 2 (3): 42-54.
6. Aruna S, Yellayi ASSR, & Rani GS. 2015. Bicornuate Uterus with Pregnancy: A Case Report and Review of Literature. *International Journal of Scientific Study*. Vol 3 (1): 231-233.
7. Souvizi B & esfehani RJ. 2016. A Case of Successful Pregnancy in a Complete Bicornuate Uterus. *JMRH*. Vol 4 (3): 712-714.
8. Connel MT, Owen CM, & Segars JH. 2013. Genetic Syndromes and Genes Involved in the Development of the Female Reproductive Tract: A Possible Role for Gene Therapy. *J Genet Syndr Gene Ther*. Vol 4: 1-22.
9. Parmaar M & Tomar S. 2014. Bicornuate Uterus: Infertility Treatment and Pregnancy Continuation without Cerclage: An Unusual Case. *Open Journal of Obstetrics and Gynecology*. Vol 4: 981-985.
10. Doruk A, Gozukara I, Burkas G, Bilik E, & Dilek TUK. 2013. Case Report Spontaneous Twin Pregnancy in Uterus Bicornis Unicollis. Hindawi Publishing Corporation.
11. Matsaseng T & Kruger TF. 2012. Laparoscopic Strassman's metroplasty for bicornuate uterus - is it relevant? *SAJOG*. Vol 18 (3): 85-87.
12. Casanova R, Chuang A, Goepfert AR, Hueppchen NA, Weiss PM, Beckmann CRB, et al. 2014. Beckmann and Lings *Obstetrics and Gynecology* Eighth Edition.
13. Bieber EJ, Sanfilippo JS, Horowitz IR, & Shafi MI. 2015. *Clinical Gynecology* Second Edition. United Kingdom: Cambridge University Press.
14. Cunningham FG, Leveno KJ, Bloom SL, Dashe JS, Hoffman BL, Casey BM, et al. *William Obstetrics* 25 th Edition. United States: Mc Graw Hill Education.