



eISSN : 2579-8324

pISSN : 2579-8323

**Address for Correspondence:**Editorial Room Andalas Obstetrics and Gynecology Journal, 3<sup>rd</sup> floor of KSM of Obstetrics and Gynecology, RSUP DR. M. Djamil Padang, Jl. Perintis Kemerdekaan Padang, Sumatera Barat 25127**Website:**<http://jurnalobgin.fk.unand.ac.id/index.php/JOE>**CASE REPORT****Thanatophoric Dysplasia**Vaulinne Basyir<sup>1</sup>, Yusrawati<sup>1</sup>, Gistin Husnul Khatimah<sup>2</sup>

*Affiliation author* : 1. Sub Division of Maternal Fetal Medicine, Obstetrics and Gynecology Department, Faculty of Medicine, Andalas University, Dr. M. Djamil Central General Hospital Padang; 2. Obstetrics and Gynecology, Faculty of Medicine, Andalas University, Dr. M. Djamil Central General Hospital Padang

*Correspondence to*: Vaulinne Basyir, email: [vaulinne@gmail.com](mailto:vaulinne@gmail.com), Hp: 08126618805

**Abstract**

**Background:** The term thanatophoric comes from the Greek word thanatophorus which means "innate death" or "bearing death". The problem that underlies this disease is the process of bone formation. This disease is associated with an autosomal dominant inherited mutation of the fibroblast growth factor 3 receptor (FGFR3) gene on the arm of chromosome 4 (4p16.3). Because FGFR3 is the main modulator in bone formation, the typical clinical features of this disease include shortening of the extremities, curved femur, clover-like skull and narrowing of the thoracic cavity. Thanatophoric dysplasia is a skeletal disorder that is "lethal" or deadly. The deaths occurred due to respiratory failure caused by reduced chest cavity capacity, hypoplastic lungs and / or brainstem compression.

**Destination:** Reported a case of thanatophoric dysplasia

**Method:** Case Report

**Case Report:** Case 33 years old woman, with preterm parturient G1P0A0H0 35-36 weeks 1 latent phase + history of 2x laparotomy + suspected fetal thanatophoric dysplasia. On ultrasound examination, it was found that BPD = 9.14 cm; AC = 30.56 cm; HC = 32.05 cm; FL = 2.55 cm; AFI; 9.06cm; SDAU = 1.72 cm. The presence of frontal bossing, saddle nose and micromelia (proximal, distal, phalanges) was found. The patient was planned for vaginal delivery and the progress of labor was followed. Patients provided informed consent regarding the possibility of fetal death during labor and after birth. During the active phase of the labor process, hypotony uterine innersia occurs and oxytocin drip is performed to accelerate labor. The baby was born male, weight 2175 grams, body length 34 cm and A / S: 1/0. Postmortem physical examination revealed macroscopic findings of thanatophoric dysplasia infants such as hypertelorism, low nasal bridge, cranio-facial disproportion. Narrow chest with protruding abdomen and short, bent limbs.

**Conclusion:** Thanatophoric dysplasia is "lethal" skeletal dysplasia. Careful prenatal examination is required in diagnosis and termination of pregnancy.

**Keywords:** Thanatophoric dysplasia, prenatal diagnosis

**INTRODUCTION**

The term thanatophoric comes from the Greek word thanatophorus which means "innate death" or "bearing death". The problem that underlies this disease is the process of bone formation. This disease is associated with an autosomal dominant inherited mutation of the fibroblast growth factor 3 receptor (FGFR3) gene on the arm of chromosome 4 (4p16.3). Because FGFR3 is the main modulator in bone formation, the characteristic clinical



eISSN : 2579-8324

pISSN : 2579-8323

**Address for Correspondence:**Editorial Room Andalas Obstetrics and Gynecology Journal, 3<sup>rd</sup> floor of KSM of Obstetrics and Gynecology, RSUP DR. M. Djamil Padang, Jl. Perintis Kemerdekaan Padang, Sumatera Barat 25127**Website:**<http://jurnalobgin.fk.unand.ac.id/index.php/JOE>

features of this disease include shortening of the extremities, curved femur, clover-like skull and narrowing of the thoracic cavity.<sup>1,2</sup>

Tannatophoric type 1 (DT-1) dysplasia is caused by several different mutations affecting the extracellular domain of FGFR3. The two R248C and Y373C mutations account for about 80% of DT-1 cases. The more common of the two TD-1 mutations is R248C with a pyrimidine C to pyrimidine T nucleotide transition impacting the extracellular domain FGFR3. While tanatophoric type 2 (DT-II) dysplasia is caused by a single mutation, K650E with the transition of purine A to purine nucleotides G in the tyrosine kinase domain FGFR3.

Clinically, tanatophoric dysplasia is divided into two subtypes, namely tanatophoric dysplasia type 1 (DT-I) and tanatophoric dysplasia type 2 (DT-II). The division of these two subtypes is divided based on the appearance of the curved or straight femur. In general, type 1 tanatophoric dysplasia (DT-I) is characterized by a curved femur, short limbs, narrow chest with or without a clover-shaped skull. Meanwhile, type 2 tanatophoric dysplasia (DT-II) is characterized by a straight femur, short limbs, narrow chest and a skull that is shaped like a clover.

Two-dimensional ultrasound can show polyhydramnios, growth deficiency, ventriculomegaly, narrowing of the thoracic cavity with short ribs, flattening of the vertebrae, and micromelia characterized by bilateral shortening of the limbs with excessive skin folds. Three-dimensional ultrasound shows better fetal face, scapular anomaly, and chest hypoplasia better than two-dimensional ultrasound.

Tanatophoric dysplasia is a skeletal disorder that is "lethal" or deadly. These deaths occur due to respiratory failure caused by reduced chest cavity capacity, lung hypoplasticity and / or brainstem compression.<sup>2,4,8</sup>

The disease has an average prevalence of 1 / 20,000 to 1 / 12,000 in prenatal cases. The incidence of this disease among men and women is the same.<sup>3,5</sup> Newborns with tanatophoric dysplasia usually die at birth or some time after birth. Death usually occurs within 48 hours and is caused by severe respiratory insufficiency resulting from reduced chest cavity and hypoplastic lung capacity or respiratory failure due to compression of the brainstem.<sup>5</sup>

## CASE REPORT

Reported a 33-years-old female patient diagnosed with preterm parturient G1P0A0H0 35-36 weeks during the 1st latent phase + history of 2x laparotomy + suspected fetal tanatophoric dysplasia. From the history, it was found that there were complaints of back pain spreading and mucus with blood since 6 hours before entering the hospital and a lot of water coming out of the genitals since 24 hours before entering the hospital. There were signs of labor in this patient. From HPHT obtained on 30/1/2020 with TP 6/10/2020. During the ANC examination, the control patient went to Sp. OG every month from 2 months of gestation



eISSN : 2579-8324

pISSN : 2579-8323

**Address for Correspondence:**Editorial Room Andalas Obstetrics and Gynecology Journal, 3<sup>rd</sup> floor of KSM of Obstetrics and Gynecology, RSUP DR. M. Djamil Padang, Jl. Perintis Kemerdekaan Padang, Sumatera Barat 25127**Website:**<http://jurnalobgin.fk.unand.ac.id/index.php/JOE>

and had known abnormalities in the fetus since 3.5 months of gestation. This is the first pregnancy after 6 years of marriage.

From the physical examination, the general condition was moderate; composmentis cooperative awareness; TD 120/80 mmHg; Pulse 82 x / min; Nf 24 x / min. From the obstetric examination, it was seen that the abdomen was bulging according to gestational age with the mid-central fundus and xyphoideus with a head presentation. The fundal height is 26 cm. Found his 2-3x / 35 " / medium and FHR 147-157 times / minute. On examination of genitalia, 3-4 cm opening, 100% effacement, anterior, amniotic membrane (-), clear remains, palpable head UUK transverse, H I-II.

Labor results show within normal limits. Hb = 14.6 gr / dl; Leukocytes = 17,430 / mm<sup>3</sup>; Ht 42%; Platelets 248,000 / mm<sup>3</sup>. On ultrasound examination, it was found that BPD = 9.14 cm; AC = 30.56 cm; HC = 32.05 cm; FL = 2.55 cm; AFI; 9.06cm; SDAU = 1.72 cm. The presence of frontal bossing, saddle nose and micromilia (proximal, distal, phalanges) was found. The patient was planned for vaginal delivery and the progress of labor was followed. Patients provided informed consent regarding the possibility of fetal death during labor and after birth. During the active phase of the labor process, hypotony uterine innersia occurs and oxytocin drip is performed to accelerate labor. The baby was born male, weight 2175 grams, body length 34 cm and A / S: 1/0.

## DISCUSSION

In this case, the patient was diagnosed with preterm parturient G1P0A0H0 35-36 weeks during the 1st latent phase + history of 2x laparotomy + suspected fetal tanatophoric dysplasia. Anamnesis was performed to predict risk factors. In addition to being part of the diagnostic, the history can also help to plan management for the mother and the patient's family. The risk factors found in this case are:

At the early age of pregnancy, the mother admitted that she experienced severe vomiting and did not want to eat. The mother also experienced weight loss. Dietary insufficiency, and nutritional insufficiency during gestation have been recognized to increase the incidence of congenital anomalies. With 400 mcg of folic acid daily in the periconceptional period, at least 1 month before conception and early pregnancy, it prevents 50-70% of neural tube defects and possibly prevents the risk of heart damage and extremities. A number of studies have examined retinoids, nitric oxide, hypoxia, vitamin D, estrogens, and micromolecules contributing to extracellular matrix molecules involved in biomechanical signaling in the regulation of chondrocyte differentiation and maturation.<sup>9,10,11</sup>

In this case the mother has known that her baby has an abnormality since 13-14 weeks of gestation, and has also done an ultrasound examination, and the fetus has skeletal dysplasia. Skeletal abnormalities become more evident with increasing gestational age, in the form of limb shortening, frontal bossing, saddle nose, and narrow chest. Frontal bossing



eISSN : 2579-8324

pISSN : 2579-8323

**Address for Correspondence:**Editorial Room Andalas Obstetrics and Gynecology Journal, 3<sup>rd</sup> floor of KSM of Obstetrics and Gynecology, RSUP DR. M. Djamil Padang, Jl. Perintis Kemerdekaan Padang, Sumatera Barat 25127**Website:**<http://jurnalobgin.fk.unand.ac.id/index.php/JOE>

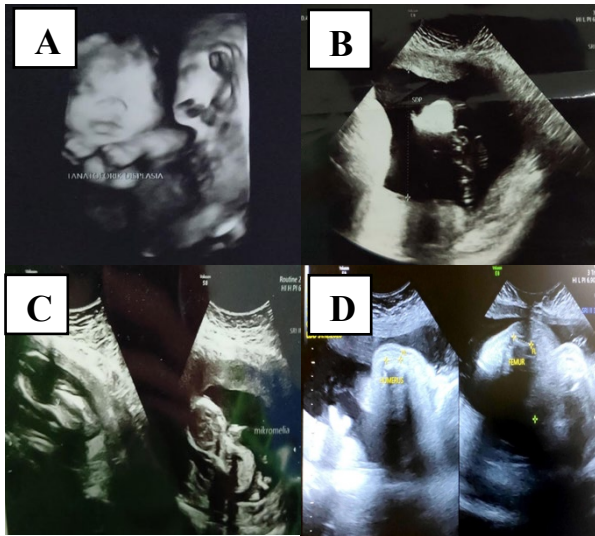
is a rounded projection of the frontal and parietal bones due to failure of development. Saddle nose is the shape of the nose bone like a horse seat, is depressed in the middle with a smaller size. Narrow chest due to the shortness of the ribs. In this case, polyhydramnios was found at 6 months of pregnancy which is thought to be due to narrowing of the esophagus so that it interferes with the resorption of amniotic fluid.<sup>12,13,14</sup>

Most cases of severe fetal skeletal dysplasia can be diagnosed by careful and repeated antenatal ultrasound during the second and third trimesters of pregnancy. On the examination can be found:<sup>15</sup>

1. Shortening of long bones <5 percentile or 3 SD
2. Platyspondyli
3. Ventriculomegaly
4. Narrowing of the chest cavity with short ribs
5. Polyhydramnios
6. Femur with bent ends
7. Abnormalities in the brain
8. Cloverleaf skull and relatively macrocephaly

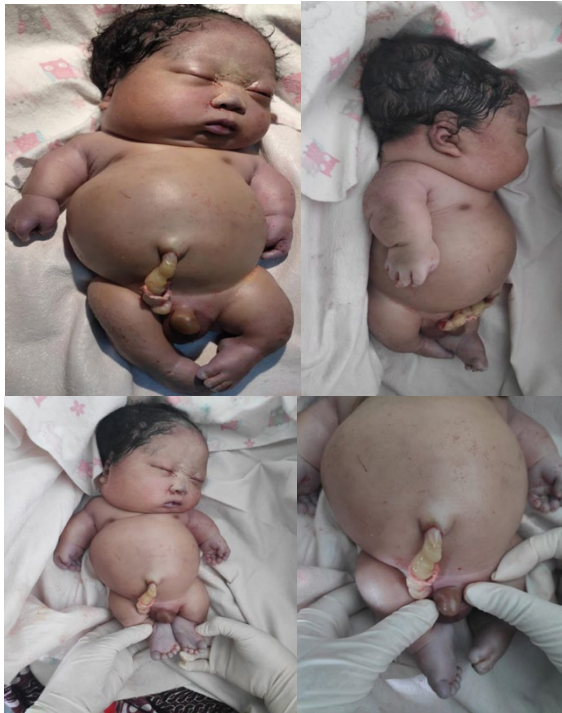Imaging this disorder is divided into 2 subtypes: a short and curved femur is characteristic for type 1, while a straight femur with a skull like basil leaves is characteristic for type 2. In patients, ultrasound of 13-14 weeks gestation shows macrocephaly and micromelia with BPD = 29.4 cm; AC = 92.5cm; FL = 0.65 cm. BPD and AC are above the 90th percentile and FL is below the 2.5 percentile for gestational age. This can differentiate it from other skeletal diseases such as acondroplasia, which have a normal femur length until 25 weeks of gestation and only begin to develop less after that.

Ultrasound examination is also of prognostic value. Measuring the ratio of thoracic circumference and abdominal circumference of <0.6, or a ratio of femur length to abdominal circumference <0.16 can predict fetal deletion.<sup>18</sup> In patients with FL / AC is 0.08 which means lethargy.



**Figure 1:** Ultrasonography of an infant than atophoric dysplasia A. Shows frontal bossing and saddle nose, B polyhydramnios, C and D. Shows short limbs.

In this case, a karyotyping was not carried out because the family did not agree. Karyotyping examination can see abnormalities in the structure and number of chromosomes that may be associated with congenital abnormalities. Postmortem examination is recommended to confirm skeletal dysplasia. Postmortem autopsy should include external examination, full body radiographs and skin or tissue biopsy for chromosome analysis, and biochemical, enzymatic, and genetic studies of the placenta. External examination will reveal macrocephaly, large anterior fontanel, frontal bossing, micromelia, bell-shaped thorax with short ribs and a protruding abdomen, bent femur.<sup>15</sup> This patient was not subjected to post mortem radiographs for moral reasons.



**Figure 2:** Postmortem examination: hypertelorism, low nasal bridge, cranio-facial disproportion, narrow chest with protruding abdomen and short, bent limbs.

## CONCLUSION

Thanatophoric dysplasia (TD) is the most common form of "lethal" skeletal dysplasia in the neonatal period. This skeletal abnormality is caused by the FGFR 3 mutation which causes proliferation disorders in the growth plate chondrocytes, so that in the end the clinical condition of the fetus appears in the form of limb shortening and prematurity of joint closure. This case reported is a case of Thanatophoric dysplasia (TD) type 1 based on prenatal ultrasound findings and postnatal physical examination although in this case the FGFR3 gene analysis was not performed.

## REFERENCES

1. Dighe M, Fligner C, Cheng E, et al. 2008. Fetal Skeletal Dysplasia: An Approach to Diagnosis with Illustrative Case. *RadioGraphics*. 28 (4): 1061-76.
2. Naveen NS, Murlimanju BV, Kumar V, Pulakunta T. 2011. Thanatophoric dysplasia: a rare entity. *Oman Med J*. 26 (3): 196-7.
3. Jung M, Park SH. 2017. Genetically confirmed thanatophoric dysplasia with fibroblast growth factor receptor 3 mutations. *Exp Mol Pathol*. 102 (2): 290-5.
4. Chen SW, Chen CP, Wang, LK, et al. 2017. Perinatal imaging findings and molecular genetic analysis of thanatophoric dysplasia type 1 in a fetus with a c.2419T> G



eISSN : 2579-8324

pISSN : 2579-8323

**Address for Correspondence:**Editorial Room Andalas Obstetrics and Gynecology Journal, 3<sup>rd</sup> floor of KSM of Obstetrics and Gynecology, RSUP DR. M. Djamil Padang, Jl. Perintis Kemerdekaan Padang, Sumatera Barat 25127**Website:**<http://jurnalobgin.fk.unand.ac.id/index.php/JOE>

- (p.Ter807Gly) (X807G) mutation in FGFR3. *Taiwanese Journal of Obstetrics and Gynecology*. 56: 87-92.
5. Nikkel SM, Major N, King WJ. 2013. Growth and development in thanatophoric dysplasia - an update 25 years later. *Clin Case Rep*. 1 (2): 75-8.
  6. Chen CP, Chang TY, Lin TW, et al. 2018. Prenatal Diagnosis of Hydrancephaly and Enlarged Cerebellum and Cisterna magna in a Fetus with Thanatophoric Dysplasia Type II and A Review of Prenatal Diagnosis of Brain Anomalies Associated with Thanatophoric Dysplasia. *Taiwanese Journal of Obstetrics and Gynecology*. 57: 119-22.
  7. Miler E, Blaser S, Shannon P, Widjaja E. 2009. Brain and Bone Abnormalities of Thanatophoric Dwarfism. *Neuroradiology / Head and Neck Imaging*. AJR: 192.
  8. Wang L, Takai Y, Baba K, et al. 2017. Can biparietal diameter-to-femur length ratio be a useful sonographic marker for screening than atophoric dysplasia since the first trimester? A literature review of case reports and a retrospective study based on 10,293 routine fetal biometry measurements. *Taiwan J Obstet Gynecol*. 56 (3): 374-8.
  9. Oliveira CIF, Fett-Conte AC. Birth defects: Risk factors and consequences. *Journal of Pediatric Genetics*. 2013; 2 (2): 85-90.
  10. López - Camelo JS, Castilla EE, Orioli IM. Folic acid flour fortification: impact on the frequencies of 52 congenital anomaly types in three South American countries. *American Journal of Medical Genetics Part A*. 2010; 152 (10): 2444-58.
  11. Shum L, Nuckolls G. The life cycle of chondrocytes in the developing skeleton. *Arthritis Research & Therapy*. 2001; 4 (2): 1
  12. Jeanty P, Valero G. The assessment of the fetus with a skeletal dysplasia.
  13. Teven CM, Farina EM, Rivas J, Reid RR. Fibroblast growth factor (FGF) is signaling in development and skeletal diseases. *Genes & Diseases*. 2014; 1 (2): 199-213.
  14. Dighe M, Fligner C, Cheng E, Warren B, Dubinsky T. Fetal Skeletal Dysplasia: An Approach to Diagnosis with Illustrative Cases 1. *Radiographics*. 2008; 28 (4): 1061-77.
  15. Karczeski B, Cutting GR. Thanatophoric dysplasia. 2013.
  16. Chitty LS, Khalil A, Barrett AN, Pajkrt E, Griffin DR, Cole TJ. Safe, accurate, prenatal diagnosis of thanatophoric dysplasia using ultrasound and free fetal DNA. *Prenatal diagnosis*. 2013; 33 (5): 416-23.
  17. Krakow D, Lachman RS, Rimoin DL. Guidelines for the prenatal diagnosis of fetal skeletal dysplasias. *Genetics IN Medicine*. 2009; 11 (2): 127-33.