

eISSN : 2579-8324

pISSN : 2579-8323

**Address for Correspondence:**Editorial Room Andalas Obstetrics and Gynecology Journal, 3<sup>rd</sup> floor of KSM of Obstetrics and Gynecology, RSUP DR. M. Djamil Padang, Jl. Perintis Kemerdekaan Padang, Sumatera Barat 25127**Website:**<http://jurnalobgin.fk.unand.ac.id/index.php/JOE>**CASE REPORT****Difficulty in Diagnosing Peritoneal Fluid Cytology in Ovarian Yolk Sac Tumor Cases**Haris Pemuda<sup>1</sup>, Yenita<sup>1</sup>, Pamela Mayorita<sup>2</sup>, Yessy Setiawati<sup>2</sup>, Syamel Muhammad<sup>3</sup>

**Affiliation authors :** 1. Dr. Achmad Mochtar District Hospital, Bukittinggi, West Sumatera, Indonesia; 2. Anatomical Pathology Department, Faculty of Medicine, Andalas University, dr. M. Djamil Central General Hospital Padang; 3. Sub Division of Gynecological Oncology, Obstetrics and Gynecology Department, Faculty of Medicine, Andalas University, Dr. M. Djamil Central General Hospital Padang  
**Correspondence to :** Haris Pemuda, email: [haris.pemuda@gmail.com](mailto:haris.pemuda@gmail.com), Hp: 082169818983

**Abstract**

**Objective :** This article objective is to describe cytology diagnosis difficulties of yolk sac tumors of the ovary.

**Method :** Case reports and literature review.


**Case :** The author reports the case of a 24 year old woman who complained of an enlarged stomach. Serum AFP increased to 16,519.7 U/mL. Ultrasound examination revealed solid and irregular mass of ovarian, so the conclusion was suspect ovarian carcinoma. Conclusion of CT scan examination was a solid ovarian tumor. The working diagnosis was suspect ovarian carcinoma. Optimal debulking was performed, accompanied by taking a sample from the peritoneal rinse fluid. Microscopic examination of peritoneal fluid showed the distribution and group of cells with pleomorphic nuclei, partly hyperchromatic, partly vesicular with coarse chromatin and prominent nucleoli. There were also cells with polygonal nuclei, small nuclei, basophilic and vacuole cytoplasm with a mucoid background. These cells formed a solid arrangement. Conclusion from these features was carcinoma metastases to the peritoneal fluid. Microscopic examination from tumor tissue sample showed an ovarian yolk sac tumor appearance.

**Conclusion :** Cytologic examination of peritoneal fluid in cases of ovarian yolk sac tumor is quite difficult to determine the diagnosis. This is due to the microscopic appearance of tumor cells which often looks like a carcinoma and limited literature about this tumors in the peritoneal fluid.

**Keywords:** Yolk sac tumor, ovary, cytology

**BACKGROUNDS**

Yolk sac tumors (endodermal sinus tumors) are primitive germ cell tumors with diverse patterns and can also show differentiation of endodermal structures, such as the primitive gastrointestinal tract and mesenchyme and derivatives of extraembryonic tissue (secondary yolk sac and allantois) and embryonic somatic tissue (intestine, liver) and mesenchyme.<sup>1</sup> Ovarian yolk sac tumors are only about 1% of all ovarian malignancies, 10% of all ovarian germ cells are malignant and are second only to dysgerminomas. These tumors often occur at a



eISSN : 2579-8324

pISSN : 2579-8323

**Address for Correspondence:**Editorial Room Andalas Obstetrics and Gynecology Journal, 3<sup>rd</sup> floor of KSM of Obstetrics and Gynecology, RSUP DR. M. Djamil Padang, Jl. Perintis Kemerdekaan Padang, Sumatera Barat 25127**Website:**<http://jurnalobgin.fk.unand.ac.id/index.php/JOE>

median age of 18 years, as many as 40% of cases occur in the prepubertal period. In rare cases, these tumors can occur in people over 40 years of age.<sup>2,3</sup>

Symptoms that are often felt by patients are abdominal pain and a mass in the pelvic area. Tumors are characterized by a rapid emergence so that symptoms are felt in a short time. Alpha-Fetoprotein (AFP), which is a constituent of human fetal serum, is produced by the yolk sac, liver and upper gastrointestinal tract. In yolk sac tumors, AFP levels rise to a median value of about 10,000 ng/mL. Extraovarian spread is found in about 30% of cases, accompanied by extensive peritoneal spread.<sup>4,5</sup>

Most of the cytological specimens in yolk sac tumors are more often obtained from fine needle aspiration examination of the metastatic area. Cytologically, the appearance of cells in yolk sac tumors is highly variable. The picture can be large polygonal cells with clear findings, vesicular nuclei and real nucleoli and can also be flattened with a few prominent nuclear features. Tumor cells can be seen to contain large cytoplasmic vacuoles so that a picture of the cell nucleus can be seen.<sup>4,6</sup>

Peritoneal fluid cytology has an important role in determining the diagnosis and staging of abdominal and gynecologic neoplasms. This procedure is also very useful in determining the management and prognosis of ovarian cancer. Spread of ovarian germ cell neoplasms into ascitic fluid was found in only a few cases, including yolk sac tumors. Ascitic fluid cytology poses a problem in the diagnosis of rare malignant neoplasms such as yolk sac tumors because there is little literature describing the cytologic findings of yolk sac tumors in peritoneal fluid. Tumor cells resembling various carcinomas can also be difficult in determining the diagnosis of ovarian yolk sac tumor in samples derived from peritoneal fluid.<sup>7,8</sup>

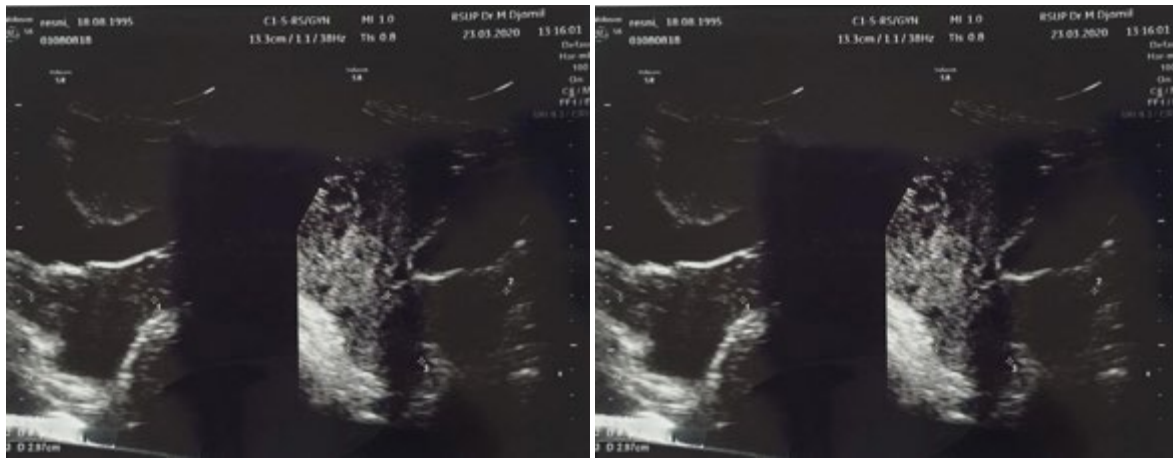
## CASE REPORT

We report a 24-year-old female patient who came to the obstetrics oncology polyclinic of RSUP M. Djamil Padang with complaints of an enlarged stomach since 9 months before admission to the hospital. The complaint is accompanied by abdominal pain and weight loss in the last 3 months. The patient had no complaints of vaginal bleeding, postcoital bleeding, vaginal discharge and fever. The patient has been married for 8 years with a history of 2 births with 2 surviving children. No complaints of defecation and urination.

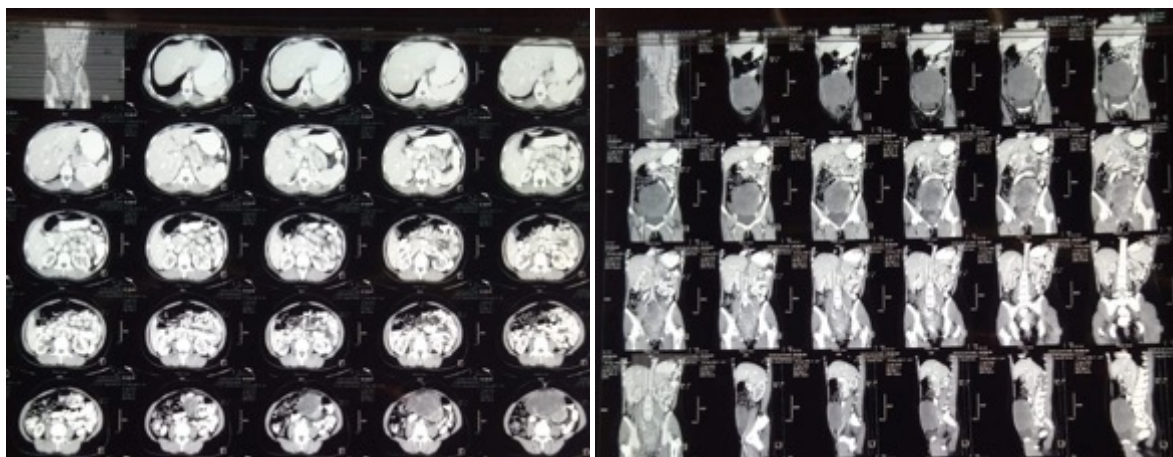
The results of inspection of the abdominal region showed an enlarged abdomen. On abdominal palpation, a palpable mass that is difficult to move in the hypogastric region with indistinct borders. Abdominal percussion revealed a dull sound in the abdominal wall at the top of the mass. On bimanual vaginal toucher (VT) examination, the lower part of the tumor was palpable in the adnexal and parametrial areas.

The results of the examination of serum AFP levels showed an increase to 16,519.7 U/mL (n=10-20 ng/mL). On ultrasound examination, the impression of a suspected ovarian

carcinoma was obtained (figure 2.1). A CT scan revealed a solid mass in the pelvic area that probably originated from the ovaries and was concluded as a solid ovarian tumor (Fig. 2.2). Based on the results of the physical examination and supporting examinations, a working diagnosis of the patient was determined as suspect ovarian carcinoma and then optimal debulking was carried out with hysterectomy accompanied by peritoneal washings fluid sampling.

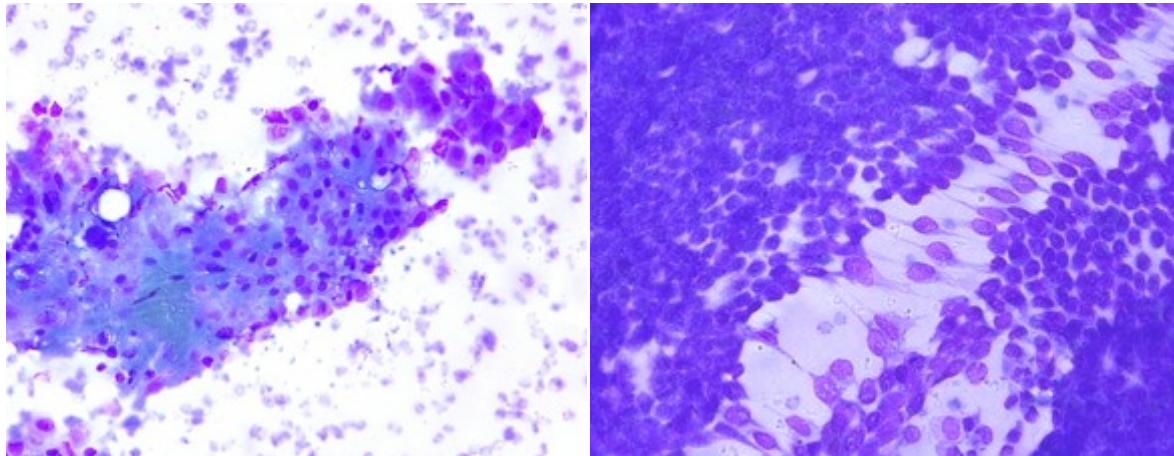


**Figure 1.** Patient Ultrasound Examination Results



**Figure 2.** The results of the CT scan of the patient A. Transverse section B. Sagittal section

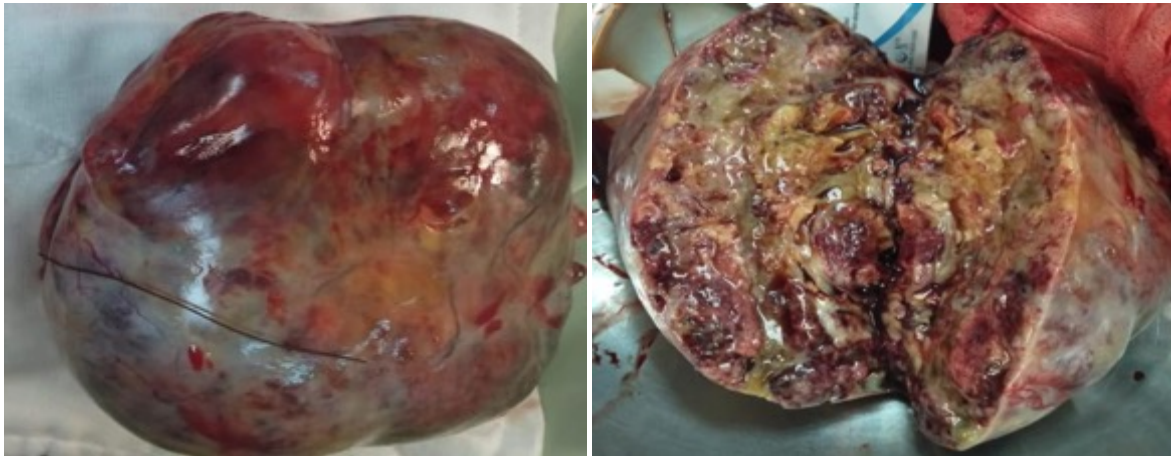Microscopic examination of the peritoneal washings fluid showed the distribution and grouping of cells with pleomorphic nuclei, some hyperchromatic, some vesicular, coarse chromatin, real nucleoli that formed a solid arrangement. Based on these microscopic findings, the impression was obtained as a metastatic carcinoma of the peritoneum.



**Figure 3.** Cytological features of the peritoneal fluid in the patient. A. Groups of tumor cells with pleomorphic nuclei arranged solidly on a mucoid background. B. cells with polygonal nuclei and some with small nuclei with basophilic and vacuolated cytoplasm.

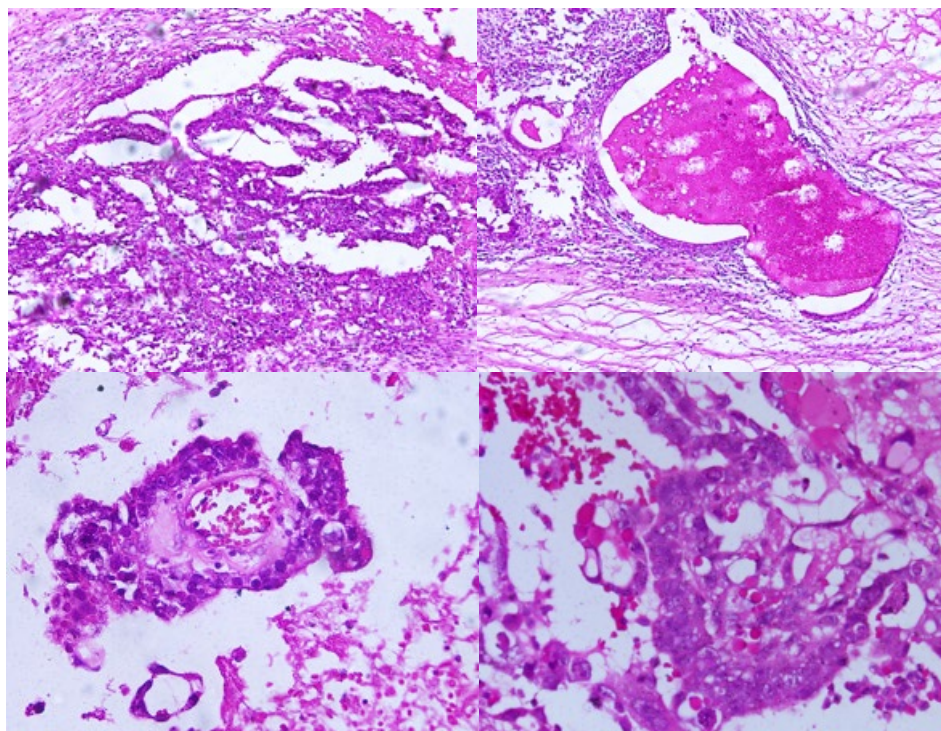
The results of the macroscopic histopathological examination of tumor tissue showed a piece of brownish white tissue, split, measuring 16x15x5 cm with a cross section of a cyst with many cavities 0.5-3 cm in diameter filled with brown and greenish fluid, some thick walls and some thin. There is also a brownish mass, brittle and slimy with areas of necrosis. Microscopic examination showed pieces of ovarian tissue consisting of connective tissue stroma, containing tumor cells with pleomorphic nuclei, vesicular, coarse chromatin, real nucleoli, atypical mitoses easily found and vacuolated cytoplasm. These cells are arranged to form a reticular structure, papillary and visible tumor cells are arranged around blood vessels (Schiller-Duval bodies). There is a picture of cavities with narrowing at the edges and the surface is lined with cuboidal-squamous epithelium (polyvesicular vitelline). In some areas, intracellular and extracellular hyaline globules and extensive foci of necrosis and hemorrhage are also seen. Microscopic appearance is appropriate for the diagnosis of ovarian yolk sac tumor. On histopathological examination of endometrial tissue, myometrium, cervix, contralateral ovary and pelvic lymph nodes, no tumor cells were found.

A review of peritoneal fluid cytology examination was carried out after histopathological examination of tumor tissue. From the results of the examination review, it was found that there were distributions and groups of cells with pleomorphic nuclei, some hyperchromatic, some vesicular, coarse chromatin, real nucleoli forming a solid arrangement. Cells with polygonal nuclei, small nuclei, cells with basophilic and vacuolated cytoplasm and clusters of cells with a mucoid background were also seen.




**Figure 4.** Macroscopic appearance of an ovarian tumor in a patient. A. The tumor tissue is intact. B. Cross section of tumor tissue.

The patient's condition was stable at 10 postoperative days. Based on the results of histopathological examination of the tissue, the patient was planned to undergo chemotherapy with a regimen of etoposide, carboplatin and bleomycin for 6 cycles.



**Figure 5.** Baby's The results of microscopic examination of ovarian tumor tissue. A. Groups of tumor cells arranged to form reticular and papillary structures. B. Tumor cells with squamous-cuboidal nuclei, forming cavities with eccentric lumen constriction (polyvesicular vitelline). C. Tumor cells with pleomorphic nuclei and vacuolated cytoplasm arranged around vascular structures (Schiller-Duval bodies). D. Description of hyaline globules found in intracellular and extracellular (arrows).



eISSN : 2579-8324

pISSN : 2579-8323


**Address for Correspondence:**Editorial Room Andalas Obstetrics and Gynecology Journal, 3<sup>rd</sup> floor of KSM of Obstetrics and Gynecology, RSUP DR. M. Djamil Padang, Jl. Perintis Kemerdekaan Padang, Sumatera Barat 25127**Website:**<http://jurnalobgin.fk.unand.ac.id/index.php/JOE>**DISCUSSION**

Yolk sac tumors generally occur in childhood and young adults with a median age of 19 years.<sup>1</sup> The age range of patients with yolk sac tumors is between 16 months and 46 years, but most of these tumors are found under 30 years of age.<sup>2</sup> Pierce et al. . stated that some evidence regarding the development of germ cell tumors suggests these tumors originate from germ cells present at an early stage of development and not from mature gonadal cells. This can explain that ovarian yolk sac tumor, which is a type of germ cell tumor, is more common in children and young adults. The biological nature of germ cells also supports the reason for the occurrence of germ cell tumors in young women. Germ cells in females will stop undergoing meiosis after birth and undergo reactivity at the age of puberty.<sup>3,4</sup>

The patient came with complaints of an enlarged stomach since 9 months before admission to the hospital and also complained of abdominal pain and weight loss in the last 3 months. Eddaoualline et al. reported a case of ovarian yolk sac tumor with patient complaints of abdominal enlargement and pelvic area distension with intermittent pain.<sup>5</sup> Tiwari. et al. also reported a case of ovarian yolk sac tumor with symptoms of abdominal distension accompanied by pain.<sup>6</sup> The most common symptom of ovarian cancer is abdominal enlargement accompanied by pain, constipation, bloating and difficulty breathing. These symptoms are caused by the effect of the enlargement of the tumor mass and the suppression of the mass on the surrounding organ structures. Other symptoms that can also accompany are weight loss, decreased appetite, bloating, fatigue. This is caused by the process of cancer cachexia which involves a series of cytokine formation processes by cancer cells.<sup>7,8</sup>

The patient's plasma AFP level was 16,519 ng/mL. Razi et al. reported a case of ovarian yolk sac tumor with a markedly elevated serum AFP level of 1156 ng/mL.<sup>9</sup> Case report by Eddaoulline et al. also showed an increase in the patient's serum AFP level to 52,330 ng/mL.<sup>5</sup> Serum AFP level in yolk sac tumors will increase far beyond the normal value (<10 ng/mL), which is >1000 ng/ml. Alpha-fetoprotein is normally produced by the yolk sac during embryonic development, so a severe proliferation of yolk sac tumor cells will cause an increase in serum AFP levels in almost all cases. Serum AFP levels are very useful in monitoring patients during and after therapy.<sup>10</sup>

Yolk sac tumors often appear cytologically to resemble various types of carcinoma. The results of cytological microscopic examination of peritoneal fluid in this case showed the distribution and grouping of cells with pleomorphic nuclei, some hyperchromatic, some vesicular, coarse chromatin, real nucleoli that formed a solid arrangement so that the diagnosis was obtained as metastatic carcinoma. Cells with polygonal nuclei, small nuclei, cells with basophilic and vacuolated cytoplasm and clusters of cells with a mucoid background were also seen. This picture is in accordance with the literature which states that the cytological picture of yolk sac tumors consists of cells with a polygonal cell nucleus and small



eISSN : 2579-8324

pISSN : 2579-8323


**ANDALAS OBSTETRICS AND GYNECOLOGY JOURNAL****Address for Correspondence:**Editorial Room Andalas Obstetrics and Gynecology Journal, 3<sup>rd</sup> floor of KSM of Obstetrics and Gynecology, RSUP DR. M. Djamil Padang, Jl. Perintis Kemerdekaan Padang, Sumatera Barat 25127**Website:**<http://jurnalobgin.fk.unand.ac.id/index.php/JOE>

size with basophilic and vacuolated cytoplasm. The mucoid background probably represents the myxomatous stroma present in the tumor.<sup>11,12</sup>

Several types of malignancy with cytological features that are often doubtful with yolk sac tumors are mucinous adenocarcinoma, embryonal carcinoma and clear cell carcinoma. Cytological features of mucinous adenocarcinoma usually show large, malignant cells with vacuolated cytoplasm that are mainly arranged in circular clusters and papillary or glandular structures are rarely seen. Cytological features of embryonic carcinoma show clusters of poorly differentiated malignant cells, irregular hyperchromatic nuclei or large vesicular nuclei with large and marked daughter nuclei. Nuclear membrane looks less clear and the cytoplasm looks pale and vacuolated. Cytological appearance of clear cell carcinoma showed cohesive tumor cells with little visible pleomorphism, clearer cell boundaries, vesicular cytoplasm, some nuclear features with thickening of the membrane and few nuclear daughters and giant cells.<sup>12,13,14</sup>

The results of microscopic examination of tumor tissue showed that pieces of ovarian tissue consisting of connective tissue stroma, containing tumor cells with pleomorphic nuclei, vesicular, coarse chromatin, real nucleoli and atypical mitoses were easy to find. These cells are arranged to form a reticular structure, papillary and visible tumor cells are arranged around blood vessels (Schiller-Duval bodies). There is also a picture of cavities with narrowing at the edges and the surface is lined by cuboidal-squamous epithelium (polyvesicular vitelline). This microscopic picture is in accordance with the literature which states that most tumor cells are arranged to form a reticular structure and can also be arranged to form various other structures, such as papillary, glandular, solid and with a polyvesicular vitelline picture. Schiller Duval bodies are a characteristic feature of yolk sac tumors.<sup>2,15</sup>

Various pathological parameters can be used as prognostic factors in these patients. The presence of a tumor in ascitic fluid or peritoneal washings can be categorized as a tumor with minimal stage IVa. This was determined based on the ovarian tumor staging system from the FIGO (Federation Internationale de Gynecologie et d'Obstetrique). Another pathological parameter that can be used is the presence of polyvesicular vitelline on microscopic examination of tumor tissue. Research by Kurman and Norris showed that as many as 29% of cases of yolk sac tumor with a polyvesicular pattern had a better survival rate than other patterns with a lower survival rate of 11%. This patient was given a chemotherapy regimen of carboplatin (platinum-based), etoposide and bleomycin. Cisplatin-based or platinum-based chemotherapy has shown a better therapeutic outcome so that it can increase the patient's survival rate. Appropriate chemotherapy can increase the survival rate in patients with ovarian yolk sac tumor.<sup>16,17,18</sup>



eISSN : 2579-8324

pISSN : 2579-8323


**Address for Correspondence:**Editorial Room Andalas Obstetrics and Gynecology Journal, 3<sup>rd</sup> floor of KSM of Obstetrics and Gynecology, RSUP DR. M. Djamil Padang, Jl. Perintis Kemerdekaan Padang, Sumatera Barat 25127**Website:**<http://jurnalobgin.fk.unand.ac.id/index.php/JOE>**CONCLUSION**

The difficulty in assessing the microscopic appearance of the peritoneal fluid in this case is the appearance of tumor cells resembling various types of carcinoma. A comprehensive examination consisting of clinical, radiological and serum AFP levels is required to direct the diagnosis. Confirmation of the diagnosis is carried out by histopathological examination of tumor tissue. The results of cytological examination of the peritoneal fluid showing the spread of malignant cells are used to determine the stage of the tumor. Staging of ovarian malignancies, especially in yolk sac tumors is very important to produce appropriate therapy and prognosis.

**REFERENCES**

1. Goldblum JR, Lamps LW, McKenney JK, et al. Yolk Sac Tumor and Embryonal Carcinoma. In: Rosai and Ackerman Surgical Pathology. 11<sup>th</sup> ed. Philadelphia: Elsevier Inc; 2018. 1394-1396 p.
2. Kurman RJ, Ellenson LH, Ronnet BM. Yolk Sac Tumor. In: Blaustein's Pathology of the Female Genital Tract. 7<sup>th</sup> ed. Cham, Switzerland: Springer Nature. 2019. 1056-1070p.
3. Pierce JL, Frazier AL, Amatruda JF. Pediatric Germ Cell Tumors: A Developmental Perspective. *Advances in Urology*. 2018; 2018: 1-8.
4. Kaatsch P, Häfner C, Calaminus G, et al. Pediatric Germ Cell Tumors From 1987 to 2011: Incidence Rates, Time Trends and Survival. *Pediatrics*. 2015; 135(1): e136-143
5. Eddaoualline H, Sami H, Rais H, et al. Ovarian Yolk Sac Tumor: A Case Report and Literature Review. *Remedy Publication LLC*. 2018; 2(1057): 1-3.
6. Sharma C, Shah H, Shenoy NS, et al. Ovarian Yolk Sac Tumor in a Girl-Case Report. *Developmental Period Medicine*. 2017; 21(2): 101-103.
7. Martin ML, Halling K, Eek D, et al. "Lower Abdominal Pains, as if I was being Squeezed...in a Clamp": A Qualitative Analysis of Symptom, Patient-Perceived Side Effects and Impacts of Ovarian Cancer. *The Patient-Patient Centered Outcomes Research*. 2020; 2020(13): 189-200.
8. Kumar V, Abbas AK, Aster JC. Effect of Tumor on Host. In: *Robbins Basic Pathology*. 10<sup>th</sup> ed. Philadelphia: Elsevier Inc; 2018. 235-236 p.
9. Razzi S, Luisi S, Gabbanini M, et al. Yolk Sac Tumor in a Young Girl: A Case Report. *Gynecological Endocrinology*. 2005; 20(6), 334-335.
10. Mutter GL, Prat J. Yolk Sac Tumor (Primitive Endodermal Tumor). In: *Pathology of the Female Reproductive Tract*. 3<sup>rd</sup> ed. Elsevier Limited; 2014. 674-678 p.
11. Orell SR, Sterrett GF. Germ Cell Tumor. In: *Fine Needle Aspiration Cytology*. 5<sup>th</sup> ed. Elsevier Limited; 2012. 366 p.





eISSN : 2579-8324

pISSN : 2579-8323

**Address for Correspondence:**Editorial Room Andalas Obstetrics and Gynecology Journal, 3<sup>rd</sup> floor of KSM of Obstetrics and Gynecology, RSUP DR. M. Djamil Padang, Jl. Perintis Kemerdekaan Padang, Sumatera Barat 25127**Website:**<http://jurnalobgin.fk.unand.ac.id/index.php/JOE>

12. Afroz N, Khan N, Chana RS. Cytodiagnosis of Yolk Sac Tumor. *Indian Journal of Pediatrics*. 2004; 71(10): 939-942.
13. Petrakakou E, Grapsa D, Stregiou ME, et al. Ascitic Fluid Cytology of Yolk Sac Tumor of the Ovary. *The International Academy of Cytology*. 2008; 53(6): 701-703.
14. Akhtar K, Hassan MJ, Khan T, et al. Yolk Sac Tumor: A Rare Case Cytological Presentation. *International Journal of Case Studies in Clinical research*. 2017; 1(6): pp 131-133.
15. Kurman RJ, Carcangiu ML, Herrington CS, et al. Yolk Sac Tumour. In: *WHO Classification of Tumours of Female Reproductive Organs*. 4<sup>th</sup> ed. Lyon: International Agency for Research on Cancer; 2014. 59 p.
16. Giorgi UD, Casadei C, Bergamini A, et al. Therapeutic Challenge for Cisplatin-Resistant Ovarian Germ Cell. *Cancers*. 2019; 11(1584): 1-14.
17. Cicin I, Saip P, Guney N, et al. Yolk Sac Tumor of the Ovary: Evolution of Clinicopathological Features and Prognostic Factors. *European Journal of Obstetrics & Gynecology and Reproductive Biology*. 2009: pp 1-5.
18. Young RH, Ulbright TM, Policarpio-Nicolas MLC. 2013. Yolk Sac Tumor With a Prominent Polyvesicular Vitelline Pattern. *American Journal of Surgical Pathology*. 2013; 37(3), 393-398.
19. Damiani D, Suci V, Genestie C, Vielh P. Cytomorphology of ovarian clear cell carcinomas in peritoneal effusions. *Cytopathology*. 2016 Dec;27(6):427-432. doi: 10.1111/cyt.12297. Epub 2016 Mar 2. PMID: 26932246.
20. Murugan P, Siddaraju N, Sridhar E, Soundararaghavan J, Habeebullah S. Unusual ovarian malignancies in ascitic fluid: a report of 2 cases. *Acta Cytol*. 2010 Jul-Aug;54(4):611-7. doi: 10.1159/000325187. PMID: 20715666.