Vol 10 No 1, 2026

ANDALAS OBSTETRICS AND GYNECOLOGY JOURNAL

*Correspondence Address:*
Editorial Room Andalas Obstetrics and Gynecology Journal, 2nd Floor Obstetrics and Gynecology Department. M. Djamil Central General Hospital Padang, Jl. Perintis Kemerdekaan Padang, West Sumatra 25127
*Website:*
*http://jurnalobgin.fk.unand.ac.id/*

eISSN : 2579-8324 pISSN : 2579-8413

CASE REPORT

# Treatment of Prepubertal Labial Adhesion: A Case Report

Ibnuzaer Khalilullah[1,*], Bobby Indra Utama[2], Yulia Margaretta Sari[2]

[1] *Obstetrics and Gynecology Department, Andalas University – M Djamil Central Hospital of Padang, West Sumatra, Indonesia*

[2] *Urogynecology Division - Obstetrics and Gynecology Department, Andalas University – M Djamil Central Hospital of Padang, West Sumatra, Indonesia*

***Corresponding Author:*** *Ibnuzaer Khalilullah, ibnuzaerkhalilullah@gmail.com*

**Submitted:** September 16, 2025; **Accepted:** January 21, 2026; **Published:** February 02, 2026
**DOI:** https://doi.org/10.25077/aoj.10.1.179-186.2026

## *Abstract*

***Introduction :*** *Labial adhesion is a condition in which the labia minora adhere to each other, either partially or completely, and is most commonly observed in prepubertal girls. The highest incidence typically occurs between the ages of 3 months and 6 years, a period during which lower estrogen levels make the vulvar mucosa more susceptible to irritation and adhesion.*
***Objective :*** *To report and discuss a rare case of labial adhesion on prepubertal.*
***Methods :*** *A prepubertal girl diagnose with labial adhesion at Dr. M. Djamil Central Hospital was reported and discuss the management.*
***Result :*** *A four-year-old girl was referred to the outpatient urogynecology clinic by a network hospital for labial adhesion. Upon general assessment, the child's development appeared appropriate for her age. Her medical history did not reveal any significant illnesses, surgical procedures, or history of sexual abuse, and her general physical examination was normal. Upon inspection, the labia majora were normal, but he labia minora appeared fused with a 0.2 cm gap at the proximal area of the adhesion. The adhesions appear thick and non-transparent For this patient, we decided to proceed with excision of the labial area without first attempting estrogen therapy. Seven days post-operation, the patient returned for a follow-up visit in good condition. The surgical wound was dry, urination was normal, and the examination showed a normal vaginal opening.*
***Conclusion:*** *From this case report, we conclude that for long-standing labial adhesion characterized by tissue thickening, labial excision is the appropriate and effective treatment option.*

***Keywords:*** *Estriol, surgical procedure, labial adhesion*

© 2026 Author. (CC BY) license.
Published by Faculty of Medicine Andalas University.

## INTRODUCTION

Labial adhesion is a condition in which the labia minora adhere to each other, either partially or completely, and is most commonly observed in prepubertal girls. The highest incidence typically occurs between the ages of 3 months and 6 years, a period during which lower estrogen levels make the vulvar mucosa more susceptible to irritation and adhesion. Additional risk factors may include recurrent urinary tract infections, dermatitis, or mild mechanical trauma.[1,2]

Labial adhesion often does not present symptoms, but in some cases, it may cause urinary difficulties or recurrent infections. Most cases improve naturally as estrogen levels rise during puberty. However, in certain instances, treatment with estrogen cream or surgical intervention may be necessary.[2]

Recent studies indicate that early intervention with estrogen cream therapy can be effective in resolving labial adhesion and preventing complications such as recurrent infections or irritation. However, more severe or recurring cases may require further evaluation and management.

## CASE REPORT

A four-year-old girl presented to the urogynaecology clinic with a complaint that her labia appeared fused. The parents only became aware of this when the child was about to undergo circumcision. The girl did not complain of any burning sensation, frequent urination, fever, or atypical vaginal discharge. Her medical history revealed no serious illnesses. There was no history of surgery, sexual abuse, or hereditary diseases. During our medical assessment, the general physical examination was normal. We informed the parents that an inspection of the external genitalia was necessary, with the possibility of photographic documentation. The child was placed on the examination bed, lying down with her mother beside her, and examined in the "frog-leg" position. Upon inspection, the labia majora were glabrous and normal for age. Moreover, the labia minora appeared fused and a 0.2 cm gap at the proximal area of the adhesion. Upon performing a sondage between the two labia, The adhesions appear thick and non-transparent. Parents were informed of the diagnosis and it was decidedato proceed with excision of the labial area without first attempting estrogen therapy.

© 2026 Author. (CC BY) license.
Published by Faculty of Medicine Andalas University.

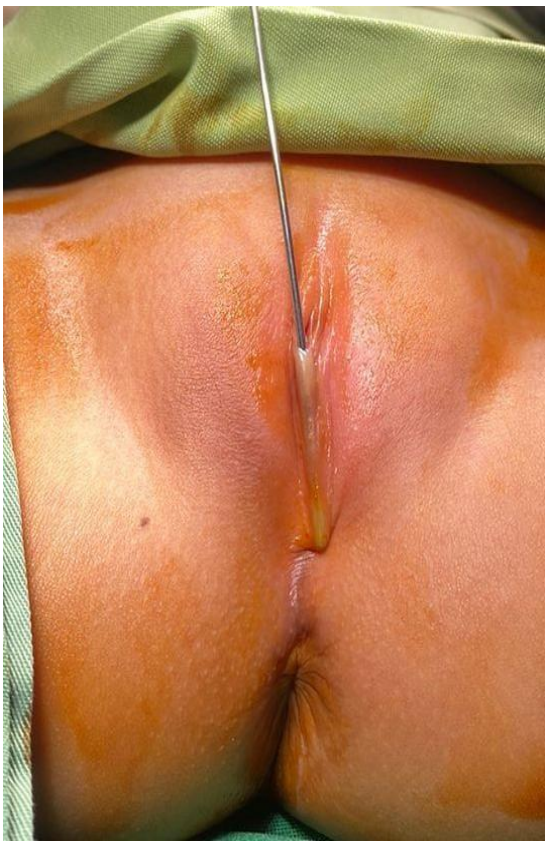

**Figure 1.** Labial adhesion at the diagnosis.

Seven days post-operation, the patient returned for a follow-up visit in good condition. The surgical wound was dry, urination was normal, and the examination showed a normal vaginal opening. (Figure 2).



**Figure 2.** Labia minora after separation procedure.

© 2026 Author. (CC BY) license.
Published by Faculty of Medicine Andalas University.

## DISCUSSION

Labial adhesion is a condition where the labia minora of the vulva become stuck together due to epithelial fusion in that area. Labial adhesion most commonly occurs in prepubertal girls, often without any noticeable symptoms, and is typically linked to low estrogen levels during childhood, which causes the vulvar mucosa to become thinner, drier, and more susceptible to irritation. Estrogen, which functions to maintain the softness and thickness of the vulvar epithelial layer during puberty and adulthood, when present in low amounts, makes the labia minora more prone to adhesion when irritation or mild trauma occurs. This irritation can arise from various sources, including poor hygiene, urinary tract infections, dermatitis, or the use of diapers and tight clothing that cause repeated friction in the genital area.[3,4] Instead, in symptomatic patients, common complaints include vulvovaginal irritation, pain during wiping and urination, discomfort with certain movements (e.g., straddle activities), or postvoid dribbling.[17] This condition usually resolves on its own with the onset of puberty, as estrogen levels increase.[3] This adhesion can partially or completely close the vaginal orifice, and although it is typically asymptomatic, it may lead to urinary issues or infections in some cases.[4]

The incidence of labial adhesion has been reported to vary, with prevalence ranging from 0.6% to 3% in prepubertal girls, particularly between the ages of 3 months and 6 years. This condition is rare after puberty due to the rise in estrogen levels. Several risk factors contribute to the development of labial adhesion, including low estrogen levels, local irritation or inflammation especially associated with diaper use, mild mechanical trauma and recurrent urinary tract infections[2,3,16,18]

Labial adhesion may be asymptomatic and is found accidentally by a physician or a caretaker or it may cause symptoms such as urinary tract infection and pain during activity, post-void dripping, and abnormal urinary stream.[22] Labial adhesion consists of fibrotic tissue that can vary from a small partial fusion to a complete fusion that obstructs the vaginal opening.[1] Partial adhesion, adhesion occurs only in a small portion of the labia minora, typically at the lower part near the perineum. This is a milder form and often does not cause significant clinical symptoms. Intermediate adhesion, adhesion involves a larger portion of the labia minora, but the urethral and vaginal orifices remain partially open. At this stage, some symptoms, such as urinary difficulties or an increased risk of urinary tract infections, may arise. Complete adhesion, In more severe cases, the labia minora may completely fuse, covering the entire urethral and vaginal orifice. This condition can lead to significant symptoms, such as urinary retention, recurrent urinary tract infections, and difficulty urinating[2-6,19] Women of the reproductive age group mostly presents with difficulty in engaging in sexual activity. Patient may not be able to pass urine in severe cases.[25]

Overall, the diagnosis of labial adhesions is primarily clinical, focusing on physical inspection of the genital area usually in the “frog leg” position and observation of symptoms related to urinary issues or vulvar irritation. Early detection and appropriate intervention are crucial, especially if there is a risk of urinary tract infection or other complications. Most girls are asymptomatic and are referred to the gynecologist due to parental or primary care provider concerns regarding an absent

© 2026 Author. (CC BY) license.
Published by Faculty of Medicine Andalas University.

or closed vagina.[11-13]

Comprehensive management of labial adhesion includes both non-surgical and surgical approaches, with treatment tailored based on the severity, clinical symptoms, and age of the patient. Non-Surgical Approach (Conservative), the first-line treatment is the use of topical estrogen. This is the most common therapy, which involves the application of topical estrogen cream (estradiol) twice daily for several weeks to a month. Topical estrogen works by enhancing the trophism (health) of the genital epithelium, which helps separate the adhesions. In mild to moderate cases, this is often effective in reducing the adhesion and improving symptoms. Estrogen cream has minimal side effects, such as slight pigmentation or irritation at the application site, but is generally safe to use in prepubertal children. In some cases, steroid cream can be used as an alternative or in combination with estrogen resulting in separation of the adhesion in about 2-8 weeks[14,15,24] Corticosteroids can help reduce inflammation and local irritation that may accompany labial adhesion. The use of corticosteroids is particularly recommended in cases where adhesion is caused by underlying inflammation or dermatitis. Corticosteroid creams (betamethasone dipropionate 0.05% or betamethasone valerate 0.1%) are applied one or two times a day for 2–12 weeks, with an average success rate reported in the literature between 15.6% and 89.5%.[12,15,18] Additionally, the use of emollients is recommended. After the adhesion is successfully separated with estrogen or corticosteroid cream, the use of emollients like petroleum jelly or other moisturizing creams is often advised to prevent recurrence of the adhesion. Emollients keep the area moist and reduce the risk of irritation, which is a major risk factor for adhesion recurrence. Some studies demonstrated that the daily topical application of Argan oil improves skin elasticity and hydration by restoring barrier function and maintaining water-holding capacity.[12,20,21] If labial adhesions do not respond to topical therapy or if the adhesion causes urinary difficulties or recurrent urinary tract infections, then manual separation or surgical intervention may be considered. This is done under local or general anesthesia, depending on the severity and the patient's comfort.[25] Surgical separation for severe or refractory cases, and although this procedure is generally simple, precautions should be taken to ensure that there is no trauma to the genital area. After manual or surgical separation of the adhesions, it is important to keep the area moist and free from irritation. Regular use of emollients and follow-up monitoring or periodic check-ups are recommended to prevent re-adhesion[3,4] Manual separation with topical antibiotics is a cost-effective method of the treatment of labial adhesion with immediate response and low recurrence rate.[23]

The prognosis for labial adhesions is generally good, especially if the condition is recognized and treated early. In many cases, adhesions can completely resolve with conservative treatments such as the use of topical estrogen creams or emollients. In mild to moderate cases, manual separation of the adhesions without surgical intervention is often successful without complications. Even in more severe cases requiring surgical intervention, postoperative outcomes are typically good if proper postoperative care is followed, such as the use of ointments to prevent re-adhesion. However, the possibility of re-adhesion remains, especially in children who have not yet reached puberty. Better outcomes are seen in patients who undergo regular monitoring and implement preventive measures for re-adhesion, including maintaining vulvar hygiene and the routine use of

© 2026 Author. (CC BY) license.
Published by Faculty of Medicine Andalas University.

emollients after separation.

## CONCLUSION

From this case report, we conclude that for long-standing labial adhesion characterized by thickening of the tissue, labial excision is the appropriate and effective treatment option.

© 2026 Author. (CC BY) license.
Published by Faculty of Medicine Andalas University.

## REFERENCES

1. Acar, N., & Degirmencioglu, S. (2019). Evaluation and Treatment of Labial Adhesions in Prepubertal Girls: A Retrospective Study. Journal of Pediatric and Adolescent Gynecology, 32(4), 400-403.
2. Leung, A. K. C., Robson, W. L. M., & Tay-Uyboco, J. (2020). Labial Adhesions in Girls: Pathophysiology and Treatment. Pediatric Dermatology, 37(5), 856-861.
3. Hoffman, B. L., Schorge, J. O., Schaffer, J. I., Halvorson, L. M., Bradshaw, K. D., & Cunningham, F. G. (2018). Williams Gynecology, 4th Edition. McGraw-Hill Education.
4. Speroff, L., & Fritz, M. A. (2015). Clinical Gynecologic Endocrinology and Infertility, 9th Edition. Lippincott Williams & Wilkins.
5. Öner, Ö., Zengin, E. B., & Caner, İ. (2019). Labial adhesions: incidence and risk factors in prepubertal girls. Journal of Pediatric Urology, 15(2), 146.e1-146.e6.
6. Gandhi, J., Joshi, G., & Smith, N. L. (2019). Labial adhesions in prepubertal girls: A comprehensive literature review. Journal of Pediatric Urology, 15(2), 156-161.
7. Bozkurt, M., Yumru, A. E., & Sahin, L. (2018). Management of labial adhesions in childhood: A review of current literature. Journal of Pediatric and Adolescent Gynecology, 31(2), 155-158.
8. Farahani, L., & Ghayyoumi, P. (2020). Labial adhesions in prepubertal girls: Diagnosis and management. Journal of Pediatric and Neonatal Care, 12(3), 89-92.
9. Ogundoyin, O., et al. (2020). Labial adhesions in childhood: Systematic review. European Journal of Pediatrics.
10. Beksac, K., et al. (2021). Labial adhesions in prepubertal children: A 5-year study. Pediatric Urology Journal.
11. Norris J.E., Elder C.V., Dunford A.M., Rampal D., Cheung C., Grover S.R. (2018). Spontaneous resolution of labial adhesions in pre-pubertal girls. J. Paediatr. Child Health. 54:748–753. doi: 10.1111/jpc.13847.
12. Murina,F., Fochesato, C., Savasi, V.M. (2024). Treatment of Prepubertal Labial Adhesions with Topical Estriol + Testosterone: A Case Report. Pediatr Rep. 16(3):558–565. doi: 10.3390/pediatric16030047
13. Vilano S.E., Robbins C.L. (2016). Common prepubertal vulvar conditions. Curr. Opin. Obstet. Gynecol. 28:359–365. doi: 10.1097/GCO.0000000000000309
14. Kim S.W., Han J.Y., Han S.J., Kim H., Ku S.Y. (2023). Effect of topical estrogen cream compared with observation in prepubertal girls with labial adhesions. J. Pediatr. Urol. 19:403.e1–403.e6. doi: 10.1016/j.jpurol.2023.01.006.
15. Huseynov M., Hakalmaz A.E. (2020). Labial Adhesion: New Classification and Treatment Protocol. J. Pediatr. Adolesc. Gynecol.33:343–348. doi: 10.1016/j.jpag.2020.03.005.
16. Ghose S, Pallavee P, Begum J, John LB, Samal SK. (2015). Labial adhesion in adult female. J South Asian Feder Obst Gynae. 7:207–209.
17. Vilano S.E., Robbins C.L. (2016). Common prepubertal vulvar conditions. Curr. Opin. Obstet. Gynecol. 28:359–365. doi: 10.1097/GCO.0000000000000309.

© 2026 Author. (CC BY) license.
Published by Faculty of Medicine Andalas University.

18. Ertürk N. (2014). Comparison of estrogen and betamethasone in the topical treatment of labial adhesions in prepubertal girls. Turk. J. Med. Sci. 44:1103–1107. doi: 10.3906/sag-1312-3.
19. Mohapatra I., Samantaray S.R. (2022). Labial Fusion Recurrence in a Prepubertal Girl: A Case Report and Review of Literature. Cureus. 14(6):e26059. doi: 10.7759/cureus.26059
20. Boucetta K.Q., Charrouf Z., Aguenaou H., Derouiche A., Bensouda Y. (2015). The effect of dietary and/or cosmetic argan oil on postmenopausal skin elasticity. Clin. Interv. Aging.10:339–349. doi: 10.2147/CIA.S71684.
21. Lin T.K., Zhong L., Santiago J.L. (2018). Anti-inflammatory and skin barrier repair effects of topical application of some plant oils. Int. J. Mol. Sci. 19:70. doi: 10.3390/ijms19010070.
22. Azarfar A, Ravanshad Y, Bagheri S, Esmaeeli M, Nejad MM. (2015). Labial Adhesion and Bacteriuria. J Turk Ger Gynecol Assoc.16(2):68–69. doi: 10.5152/jtgga.2015.15222
23. Dhaiban M.A.R., Chaudary M.A. (2021). Manual Separation of Labial Synechiae: A Cost-Effective Method in Prepubertal Girls. Afr J Paediatr Surg. 18(3):139–142. doi: 10.4103/ajps.AJPS_34_20
24. Huseynov M. (2019). Pre-pubertal labial adhesion surgery: The first study to compare manual or surgical separation. Annals of Medical Research. 26(6):991-4. DOI: 10.5455/annalsmedres.2019.03.135
25. Amin K., Khadikar B., Rajput H., Patel K. (2021). An unusual case of labial fusion in a post pubertal girl. International Journal of Reproduction, Contraception, Obstetrics and Gynecology Int J Reprod Contracept Obstet Gynecol. 10(7):2890-2892

© 2026 Author. (CC BY) license.
Published by Faculty of Medicine Andalas University.